

# wavelength

## SPINE 2

SRS Matures into  
Mainstream Extra-  
cranial Technique

## LUNG 6

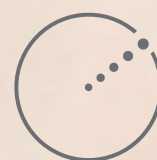Dr. Robert Timmerman  
Discusses SBRT for  
Inoperable Lung Cancer

## BRAIN 15

Seeing Clearly  
with Extend

## BREAST 22

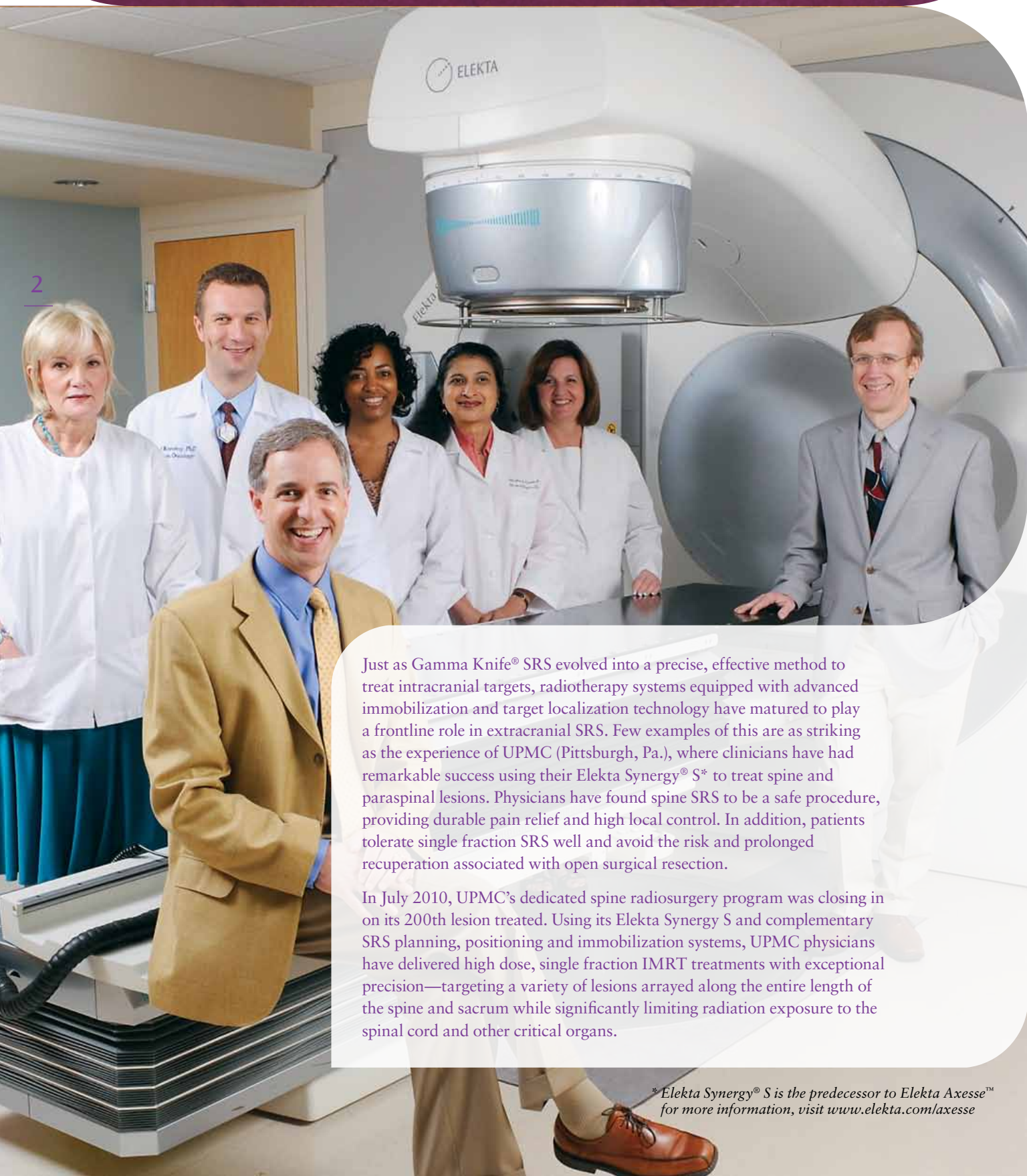
Ground Breaking  
Soft Tissue Visualization



ELEKTA

# Stereotactic Radiosurgery Matures Into Mainstream Extracranial Technique

University of Pittsburgh Medical Center's (UPMC) Elekta Synergy S is Centerpiece of Stereotactic Radiosurgery (SRS) Program for Spine Lesions



2

Just as Gamma Knife® SRS evolved into a precise, effective method to treat intracranial targets, radiotherapy systems equipped with advanced immobilization and target localization technology have matured to play a frontline role in extracranial SRS. Few examples of this are as striking as the experience of UPMC (Pittsburgh, Pa.), where clinicians have had remarkable success using their Elekta Synergy® S\* to treat spine and paraspinal lesions. Physicians have found spine SRS to be a safe procedure, providing durable pain relief and high local control. In addition, patients tolerate single fraction SRS well and avoid the risk and prolonged recuperation associated with open surgical resection.

In July 2010, UPMC's dedicated spine radiosurgery program was closing in on its 200th lesion treated. Using its Elekta Synergy S and complementary SRS planning, positioning and immobilization systems, UPMC physicians have delivered high dose, single fraction IMRT treatments with exceptional precision—targeting a variety of lesions arrayed along the entire length of the spine and sacrum while significantly limiting radiation exposure to the spinal cord and other critical organs.

*\*Elekta Synergy® S is the predecessor to Elekta Axesse™ for more information, visit [www.elekta.com/axesse](http://www.elekta.com/axesse)*

## UPMC'S INITIAL EXPERIENCES WITH EXTRACRANIAL SRS BEGAN A DECADE AGO, AS CLINICIANS WORKED TO ADAPT INTRACRANIAL SRS TECHNIQUES TO LESIONS OUTSIDE THE HEAD.

*“Extracranial radiosurgery evolved from intracranial radiosurgery,” says Peter C. Gerszten, M.D., M.P.H., Associate Professor of Neurological Surgery and Radiation Oncology, and a pioneer in spine SRS. “We adopted many intracranial radiosurgery techniques, such as applicable doses and what to contour and what not to contour. We then combined that knowledge with the immobilization and positioning technologies that extracranial treatments require. Because so many patients need this kind of treatment, our experience has grown. Many spine surgeons around the country and the world refer their patients to our center because they know we can help them when no practical therapeutic options remain. There are no therapies, no surgeries, no more types of radiation, but here in Pittsburgh we can offer patients this treatment.”*

Using a variety of treatment systems over the years, UPMC has the largest experience with spine radiosurgery in the world, having treated close to 2,000 patients. In 2009, the Department of Neurological Surgery performed over 10,000 surgical procedures and is among the busiest neurosurgery departments in the country.

### First Large SRS Patient Series Evaluated

Since UPMC launched its Elekta Synergy S spine SRS program in 2007, Gerszten et al. have conducted two evaluations, one on setup accuracy using CBCT image guidance in patients with spinal implants<sup>1</sup> and one summarizing treatment results of the program's first 108 patients, encompassing 166 spine and paraspinal lesions (in press).<sup>2</sup>

*“The intent of spine radiosurgery is to improve local control over conventional fractionated radiation therapy, decrease pain and achieve a level of effectiveness with an*

*acceptable safety profile for previously irradiated lesions,”* Dr. Gerszten notes.

Among the program's first 108 patients, lesions were located in all regions of the spine and most had metastasized from primary sites such as the breast and lung and included sarcomas and renal metastases. Eighty-two percent of the cases were malignant lesions and nearly one-fifth were intradural—close to or inside the spinal cord itself. Of note is that one-third of the patients had previously implanted titanium spinal instrumentation and/or methylmethacrylate bone cement at the treated level (see Spinal hardware no problem for CBCT).

*“We don't just do straightforward cases of palliation for spinal metastases—we treat some very complex, intradural and even intramedullary lesions, some of them benign,”* he says. *“Some say you need pencil beam technology to provide the necessary conformality and accuracy, but we can accomplish it with Beam Modulator™ micromultileaf collimator from Elekta.”*

Beam Modulator is a critical component of an integrated solution that satisfies the major requirements of extracranial SRS in general and spine SRS in particular (see The right tool for the task).

### Superior Target Localization and Delivery Enable High Dose in a Single Fraction

Spine SRS can be completed in a single fraction by virtue of a high dose, which provides a high biologic equivalent dose (BED).

*“We prefer to use one fraction versus multiple fractions for the vast majority of these SRS cases,”* Dr. Gerszten observes. *“Plus, a single fraction is so much more convenient for patients and more efficient from a technology utilization perspective.”*

To enable a high dose, the treatment plan must tightly conform the prescribed dose to the target, while featuring steep dose gradients at the edge and the immediately surrounding normal tissue. Accordingly, initial target localization is critical, so patients receive a fine cut CT simulation while immobilized with BodyFIX® from Elekta or a head/shoulder mask. MR imaging using 1-2 mm slice thickness is frequently fused to the CT simulation for contouring purposes.

*“The MRI is very helpful for obtaining optimal conspicuity between the lesion and spinal cord, particularly if the lesion is very close to the spinal cord,”* says radiation oncologist and spine SRS team member, John C. Flickinger, M.D.

In approximately 25 percent of the cases, a recent PET-CT scan also is available. CT simulation, MRI, and available PET-CT images are fused, and Drs. Flickinger and Gerszten use the fused dataset to contour the target, spinal cord and other critical anatomy. The contours are exported to the treatment planning system and the clinicians provide Mubina Quader, Ph.D. and Josef Novotny, Ph.D., physicists and spine SRS team members, with applicable doses and dose constraints to develop the plan.

In the prospective evaluation of the program's first 108 spine SRS patients, the prescribed dose to the edge of the GTV was 12-20 Gy (mean 16 Gy). Nine to 14 coplanar beams (mean 9 beams) using IMRT were used to deliver the total dose to the target volume.

To measure intra-fraction patient movement, UPMC's protocol specifies CBCT scans obtained immediately before, at the first third, and at the second third of the treatment. At the program's inception, these were quality assurance scans to assess deviations from the planning scans.

-continued-

Peter Gerszten MD, MPH and John Flickinger MD; back row: Valerie Dewald, R.T.(P); Josef Novotny, PhD; Stephanie Mungin, RN, BSN; Mubina Quader, PhD and Carol Kennedy, RN.

# Stereotactic Radiosurgery Matures Into Mainstream Extracranial Technique

4

*“We included a second and third CBCT scan at the middle and end of the treatment for the first 50 patients because I wanted to have confidence in the precision of this frameless treatment,”* Dr. Quader says.

This practice was modified and incorporated into the protocol to provide a way to further increase treatment accuracy even when needed corrections are minuscule.

*“When we do the CBCT scan we always apply whatever correction is necessary, even if it is half a millimeter,”* she adds. *“If you can see the positioning discrepancy, why not fix it?”*

The HexaPOD™ table from Elekta easily facilitates all positioning corrections in six directions of freedom and with submillimeter precision.

These CBCT image guidance data from the prospective study demonstrated that treatment delivery was extremely accurate in the three translational and three rotational directions, providing an overall translational position accuracy of less than 2 mm.

## Centers Consistent On Positive SRS Outcomes

At UPMC and 28 other centers performing spine SRS independent of each other, 85 percent to 100 percent of reported patients experienced effective pain palliation and 57 percent to 92 percent experienced improvement of progressive neurologic symptoms after radiosurgery. Local control

rates of 75 percent to 100 percent have been reported in single-institution reports, and most of the reported local control rates are approximately 90 percent.<sup>3</sup>

*“These are individual centers reporting, and there are no randomized data available to date to make a conclusion based on high-level evidence,”* Dr. Gerszten notes. *“Still, a strong recommendation can be made that radiosurgery should be considered over conventional fractionated radiotherapy for the treatment of solid-tumor spine metastases in the setting of oligometastatic disease and/or radioresistant histology in which no relative contraindications exist.”*

In terms of radiation toxicity, in UPMC’s prospective study, no evidence of acute or subacute radiation induced spinal cord toxicity has been observed among this series at a median follow-up of 15 months.

*“Spine SRS is remarkably well tolerated compared to open surgery, and the rapidity of symptomatic improvement can be striking,”* according to Dr. Gerszten.

He cites a case in which a 35-year-old school teacher presented with right proximal leg pain. An MRI and subsequent CT-guided biopsy revealed a right L1 level intradural hemangioblastoma. The patient was referred for radiosurgery to avoid the risks and protracted convalescence of open surgery.

*“In a single fraction, we used 11 coplanar beams to treat the 17.2*

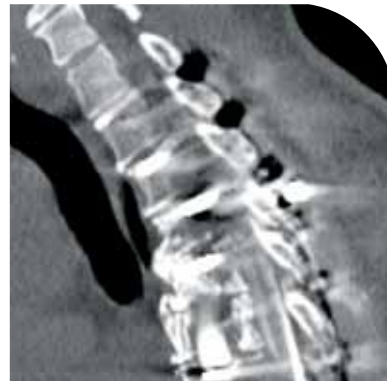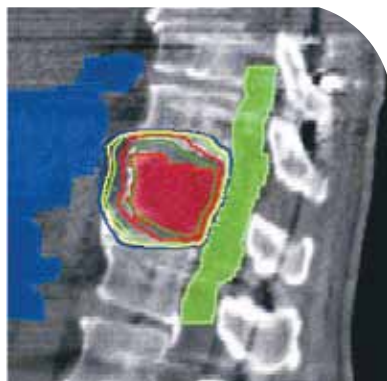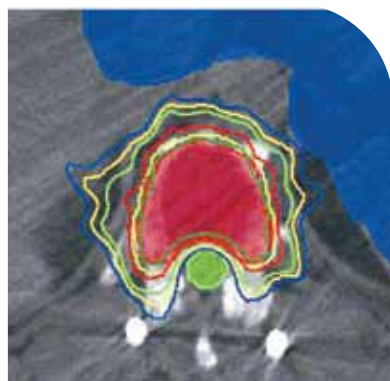
*cm<sup>3</sup> GTV with 15 Gy to the tumor’s edge,”* he notes. *“The patient reported complete pain resolution within one month with no evidence of tumor progression on an imaging study 18 months later. He didn’t have to miss a single day of work.”*

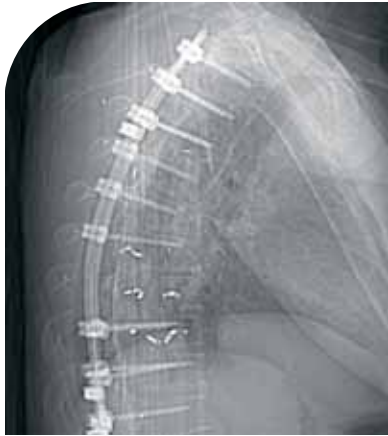## Evolution of Extracranial SRS to Continue

With the introduction of effective target localization and immobilization technologies, the techniques of intracranial radiosurgery have made a successful leap to extracranial applications. In the hands of skilled UPMC clinicians, the complete Elekta Synergy S solution for radiosurgery of the spine, in particular, addresses all the requirements for patient setup, immobilization, planning, field shaping, image-guidance and position correction.

The science of spine radiosurgery is about to get a boost as well. A phase II/III prospective, randomized study being conducted by the Radiation Therapy Oncology Group (RTOG 0631) is currently enrolling patients. The Phase II objective is to determine the feasibility of image-guided SRS for spine metastases in a cooperative group setting. The Phase III objective is to determine whether spine SRS improves pain control as compared to conventional external beam radiotherapy.

*“This study would be a great opportunity for centers that use of Elekta Synergy S or a functionally similar treatment system to participate in advancing this discipline,”* he says.





## Spinal Hardware— No Problem for CBCT

Many patients with spine metastases have been implanted with titanium instrumentation or methylmethacrylate to support vertebrae weakened by their disease. Dr. Gerszten et al. prospectively studied how the presence of orthopedic hardware at the treatment site would affect the accuracy of CBCT image guidance for treatment setup in 31 implanted patients.<sup>1</sup>

*“There was a concern about the ability to accurately and safely perform spine radiosurgery in these cases because the implants can interfere with certain image guidance systems used for accurate patient setup and tumor targeting,”* Dr. Gerszten observes.

In the UPMC study, three QA CBCT scans were performed to measure patient movement: before, halfway through and after radiosurgery. Researchers analyzed the positioning data and fused images of planning CTs and CBCTs to determine intrafractional patient movements. CBCT provided acceptable visualization of the target despite the presence of implants. On average, all translational variations were in the submillimeter range.

*“CBCT for patient setup in single fraction SRS appears to be feasible and safe in this patient group,”* he says.

Approximately one-third of UPMC’s spine SRS patients have spinal instrumentation or methylmethacrylate in place at the time of treatment.

## Right Tool for the Task

While UPMC has other platforms with which to perform extracranial SRS (e.g., Trilogy, CyberKnife), Elekta’s unified solution meets all specific requirements for the technique, according to Dr. Gerszten.

UPMC’s Elekta Synergy S 6-MV linear accelerator has the integrated X-ray Volume Imaging (cone beam CT) image guidance system and Beam Modulator, featuring 4.0 mm leaves. The treatment system also is equipped with a HexaPOD couch that enables patient positioning correction in three translational (x, y, z) and three rotational (yaw, pitch, roll) directions. Patients are immobilized with BodyFIX dual vacuum technology body bag when treatment sites are caudal to T6; otherwise, a head and shoulder mask with S-board from CIVCO is employed. Planning is performed with Philips Pinnacle.

*“The image quality of the cone beam CT is very good, as are the patient setup and ease of using this technology,”* he observes. *“We’re finding that a third of our patients have spinal instrumentation, so we need technology that can incorporate and track off of these devices and materials. We wanted something that could deliver single fraction radiosurgery very quickly with good fusion of MR and PET-CT images. Elekta Synergy S is an extracranial neurosurgery tool that works very well for us. It meets the requirements for a spine radiosurgery program.”*

<sup>1</sup> Gerszten PC, Monaco IE, Quader M, Novotny Jr J, Kim JO, Flickinger JC, Huq MS: Setup accuracy of spine radiosurgery using cone beam computed tomography image guidance in patients with spinal implants. *J Neurosurg Spine* 12:413-420, 2010.

<sup>2</sup> Gerszten PC, Novotny Jr J, Quader M, Dewald VC, Flickinger JC: Prospective evaluation of a dedicated spine radiosurgery program using Elekta Synergy S. (*J Neurosurg*, in press, December 2010)

<sup>3</sup> Gerszten PC, Yamada Y, Mendel E: Radiotherapy and radiosurgery for metastatic spine disease: What are the options, indications and outcomes? *SPINE*, 34:S78-S92, 2009.

