



innovative

## *UPMC advances minimally invasive spine surgery techniques*

by William C. Welch, MD, FACS, FICS & Peter C. Gerszten, MD, MPH

quick recovery

cost-effective

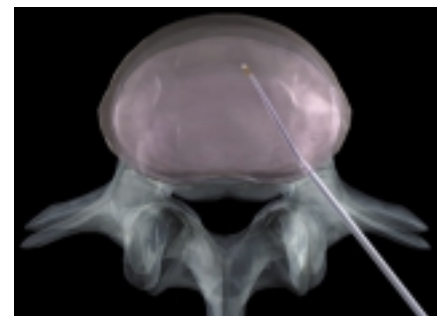**T**he Department of Neurological Surgery has witnessed and helped advance minimally invasive, minimal access spine surgery. There has been a trend towards smaller incisions and less localized trauma to the perineural tissues in an effort to improve clinical outcomes. A secondary benefit of these approaches may be shortened hospital stays.

Minimally invasive or minimal access spinal surgery has been advocated for certain lumbar and cervical pathology, such as disc ruptures. Earlier attempts at minimal access techniques were hindered by limitations in visualization, physician non-familiarity with minimal-access technologies, and lack of availability of high-quality commercially-available surgical adjuncts such as minimal access ports and endoscopes.

Spine surgeons now perform minimal access procedures on a routine basis. These procedures employ technologies which were not available until recently. Each technique builds upon and supplements traditional surgical approaches. The following is a description of the latest technologies and their applications in spinal surgery.

### **Nucleoplasty™**

The Nucleoplasty device is a catheter that creates a small, highly localized plasma field. This catheter is percutaneously inserted into the intervertebral disc through a stylet. The location is confirmed using fluoroscopy. The catheter is activated and gentle movements are made to the catheter as it lies within the disc space. In this way, small amounts of disc material may be ablated within the disc space and disc decompression may be obtained. This technique is percutaneous and does not require any incision. It is most useful in patients with nerve root irritation due to smaller disc bulges or contained ruptures.

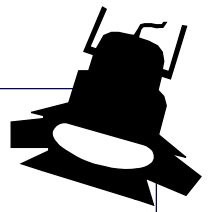


▲ **Nucleoplasty™ procedure.**

### **Intradiscal Electrothermy (IDET)**

IDET is similar to Nucleoplasty in that it is a percutaneous procedure that requires the insertion of a stylette into the disc space. This outpatient procedure is directed towards patients with symptomatic degenerative disc disease. This technique involves the insertion of a small-bore needle into the involved disc segment of a patient. General anesthesia is avoided in most patients and intravenous sedation is utilized. A catheter with a thermal tip is inserted through the needle and is coiled in the disc. The catheter tip is heated for 15 minutes, and the assembly is removed. We have prospectively examined patient outcomes and have found the technique to provide satisfactory lower back pain relief in 75% of patients treated.

(see *Minimally invasive spine surgery* on page 6)



**Professors**

L. Dade Lunsford, MD  
(Chairman)  
A. Leland Albright, MD  
Douglas Kondziolka, MD, MSc  
Donald W. Marion, MD, MSc  
Walter D. Obrist, PhD  
(Emeritus)  
Ian F. Pollack, MD  
Robert Sclabassi, MD, PhD  
Howard Yonas, MD  
(Vice Chairman, Academic Affairs)

**Associate Professors**

P. David Adelson, MD  
Jeffrey Balzer, PhD  
C. Edward Dixon, PhD  
Michael Horowitz, MD  
Larry W. Jenkins, PhD  
Donald Krieger, PhD  
John J. Moossy, MD  
Mingui Sun, PhD  
John K. Vries, MD  
William C. Welch, MD

**Assistant Professors**

David Bissonette, PA-C, MBA  
(Assistant Chairman/Executive Director)  
Donald J. Crammond, PhD  
Peter Gerszten, MD, MPH  
Glenn Gobbel, DVM, PhD  
Amin Kassam, MD  
Joseph T. King, Jr., MD, MSCE  
Ann H. Maitz, MSc  
Hideho Okada, MD, PhD  
Michael J. Rutigliano, MD, MBA  
Harold B. Weiss, MS, MPH, PhD

**Clinical Professors**

Joseph C. Maroon, MD  
(Vice Chairman)  
Peter Sheptak, MD  
(Vice Chairman, Clinical Affairs)

**Clinical Associate Professor**

Adnan A. Abla, MD

**Clinical Assistant Professors**

Ghassan K. Bejjani, MD  
Matt El-Kadi, MD, PhD  
Daniel A. Wecht, MD

**Research Professor**

Edwin Nemoto, PhD

**Research Associate Professors**

John Herron, PhD

**Research Assistant Professors**

Ronda Pindzola, PhD  
Ajay Niranjani, MCh

**Visiting Assistant Professor**

Anthony Fabio, PhD

**Research Instructor**

Wendy Fellows-Mayle, MA

**Visiting Instructor**

Catherine A. Mazzola, MD  
Jonathan D. Sherman, MD

**Spotlight: Endovascular Neurosurgery**

**Dr. Michael Horowitz**

(Note: Endovascular neurosurgery is a catheter-based subspecialty dedicated to the minimally invasive management of neurologic vascular and neoplastic disease via a transfemoral arterial or venous route. In July of 1999, Michael Horowitz, MD, joined the University of Pittsburgh's Department of Neurosurgery to head up its interventional endovascular effort.)

Born and raised in New York, Dr. Horowitz majored in biology at Williams College where he did research on spinal cord regeneration. He obtained his medical degree from the University of Rochester in 1988. Dr. Horowitz went on to complete his residency in Neurological Surgery at the University of Pittsburgh in 1994. Following his residency he fulfilled a two year fellowship in interventional endovascular neurosurgery at Southwestern Medical Center in Dallas.



From 1996 to 1999, Dr. Horowitz was Assistant Professor of Neurosurgery and Radiology at Southwestern University Medical Center specializing in the open surgical and endovascular management of vascular disease. He became Board Certified in Neurological Surgery in 1996 and returned to Pittsburgh in 1999 where he is currently associate professor of neurosurgery and radiology at the University of Pittsburgh.

Dr. Horowitz has published over 50 articles and book chapters and has delivered over 100 invited lectures relating to the management of neurosurgical disorders. He is a member of the American Association of Neurological Surgeons, the Congress of Neurological Surgeons, and the American Society of Interventional and Therapeutic Neuroradiology. He is an *ad hoc* reviewer for the journal *Neurosurgery*.

His particular interests include treatment of acute ischemic stroke, cerebral aneurysms, arteriovenous malformations, arterial stenoses, and tumors. In addition to

performing over 200 radiologic procedures per year, Dr. Horowitz is also the assistant director of the Cranial Nerve Disorders Center where he and director Amin Kassam, MD, assistant professor of neurosurgery and otolaryngology, specialize in the microsurgical management of a diverse group of disorders which include trigeminal neuralgia, hemifacial spasm, tinnitus, glossopharyngeal neuralgia, and occipital neuralgia. Together they see over 500 patients per year with these disorders and operate on approximately 180 individuals who are felt to be surgical candidates. Other

interests include diagnosis and management of normal pressure hydrocephalus.

Aside from his endovascular and open surgical efforts, Dr. Horowitz is a member of the UPMC Innovative Practices Committee,

is one of the founding members of the Center for the Assessment of Surgical Technologies at UPMC, and is a consultant for Target Therapeutics, Inc., KLS Martin, Inc. and Seacoast Technologies.

He and others in his department — including Drs. Kassam, William Welch, associate professor of neurosurgery and director of spinal surgery, and Robert Sclabassi, professor of neurosurgery and engineering — work with a variety of entities to develop and test new and innovative ways to make neurosurgical procedures less invasive and more effective.

In the future, Dr. Horowitz hopes to expand the scope of endovascular surgery at UPMC keeping it one of the nation's premier centers for minimally invasive vascular surgery. He believes this can be achieved through review and publication of results, innovative practice, and focus on improvement in patient outcomes. ■

▲ **Dr. Horowitz explains the anatomy of the brain to a third grade class.**

## Microdiscectomy remains 'gold standard' for disc resection

by Joseph C. Maroon, MD

I now have personal operative experience with over 2,500 microdiscectomies. After investigating and using almost all percutaneous and standard operative techniques, I believe that the microsurgical approach for lumbar discectomy remains the gold standard against which all other procedures must compare.

During surgery, a 15-25 mm skin incision is made just lateral to the appropriate spinous processes, the lumbodorsal fascia is incised 2 mm from its insertion and a subperiosteal dissection exposes the inferior third of the lamina above, the ligamentum flavum, the medial facet and the upper portion of the inferior lamina.

The operating microscope with a 300-mm objective is then brought into use. A low profile, high speed drill (Anspach or MedNext) with a 4-5 mm coarse diamond bit is used to thin the inferior lamina, medial facet and superior lamina surrounding the interspace. One, two and three millimeter rongeurs are used to remove the ligamentum flavum as needed but the medial portion is usually preserved so that it still overlies the nerve root.

The remainder of the operation is performed in the standard fashion. The disc is palpated with a blunt dissector or right angle nerve hook, and the nerve root is retracted with a blunt section tip. Free fragments are removed from the epidural space and then the posterior longitudinal ligament is incised and nuclear material is removed in the standard fashion (*see photo, bottom right*). After thorough exploration superiorly, medially and inferiorly and a foraminotomy is completed, the fascia is closed with 2-3 sutures and the skin with a subcutaneous stitch. Steri strips and a band-aid are applied to the wound.

Patients are urged to ambulate immediately and are discharged within 23 hours, either the same day or the following morning in 95% of the cases. The average operating time is less than one hour. Approximately 90% of patients obtain good to excellent pain relief. Complications such as dural tears, nerve root injury and discitis are under 1.5%. Long term reoperations at the same level are under 5%. No transfusions, great vessel or retroperitoneal injuries or mortality has occurred in over 2,500 operations.

To reduce perineural fibrosis we preserve, as much as possible, the epidural fat and ligamentum flavum over the nerve root. If it is necessary to do a more extensive dissection, Adcon-L® is used in the epidural space.

When one compares the surgical outcome and overall experience with microsurgical discectomy with

percutaneous techniques such as chemonucleolysis, automated percutaneous lumbar discectomy, modified nucleotomy and transforaminal endoscopic techniques the microsurgical approach appears to be superior in most areas. Obviously, laser discectomy has no place with extruded or sequestered fragments and none of the other techniques deal with lateral recess or foraminal stenosis, hypertrophy of the ligamentum flavum or osteophytes that occasionally are encountered unawares.

A valid comparison can be drawn between the micro-endoscopic technique and the strict microsurgical method. Proponents of MED assert that the primary differences with the microsurgical approach are 1) a smaller skin incision, 2) a muscle splitting rather than a subperiosteal approach to the lamina, 3) less post-operative pain, 4) faster hospital discharge and 5) a quicker return to employment. Once exposure through the tubular endoscopic system is obtained, the endoscopic technique for ligamentum flavum removal, discectomy and foraminotomy are the same as that used in the microsurgical approach.

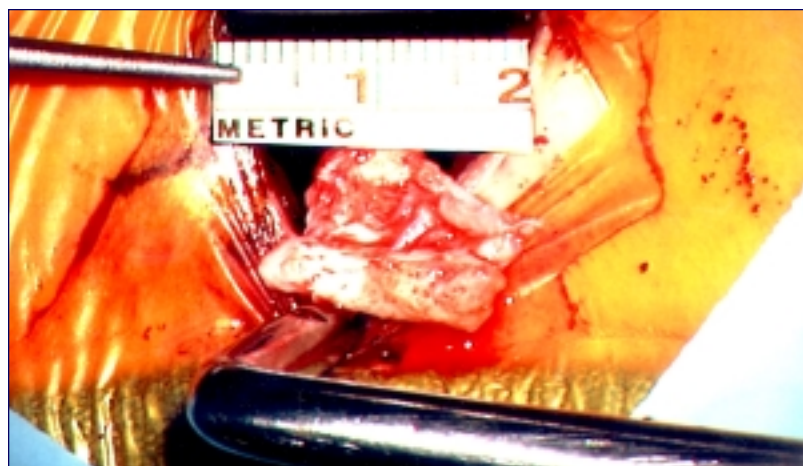
We, and others, have demonstrated the incision size, hospital stay and results are at least equivalent to that reported with the MED system. The return to work interval is also comparable. Recently, we returned an NFL defensive end to football in one month after microsurgery for an extruded fragment.

With the tremendous advances in neuro imaging, better understanding of the pathophysiology of disc disease and the innovations in technological development, pursuit of unique and minimally invasive ways to treat lumbar disc disease must continue. Nevertheless, it is our conclusion that in the year 2001 microsurgical discectomy remains the procedure of choice for the majority of patients requiring surgery and continues to be the standard against which all other procedures must be measured. ■



▲  
**Dr. Maroon**  
Heindl Scholar and  
Clinical Professor  
of Neurological Surgery

Disc fragments  
being removed  
through 2mm  
incision during  
microdiscectomy.



## Intradiscal electrotherapy (IDET), Nucleoplasty™ offer promising options for lumbar disc disease treatment



▲  
**Dr. Welch**  
Director, Neurosurgical  
Spine Services

by William C. Welch, MD, FACS, FICS

Sciatica is a condition where one of the lower lumbar or first sacral nerve root is irritated. This results in pain radiating down the leg and may cause numbness, weakness, bladder, bowel or sexual dysfunction. 75-90% of patients with sciatica caused by a disc rupture will get better without specific therapy. Bed rest has been shown to be less effective than early return to regular activities. Physical therapy and corticosteroids given either orally or via epidural injections may help to reduce the pain.

The standard treatment for symptomatic lumbar disc rupture causing sciatica remains the microdiscectomy. Indeed, over 90% of patients undergoing microdiscectomy for sciatica will report good to excellent relief of their leg pain. Patients generally leave the hospital the same or next day and can return to sedentary work in a few days to a few weeks. All new treatments are compared against this "gold standard."

The newest and most promising minimally-invasive techniques for the surgical treatment of symptomatic lumbar disc disease are the intradiscal electrotherapy (IDET) treatment and the Nucleoplasty™ procedure.

We have performed the IDET procedure as a prospective, institutional review board approved study in over 60 patients at UPMC Presbyterian and UPMC Shadyside. The treatment involves the insertion of a needle and catheter system into the disc. The tip of the catheter has a thermal resistance coupler and heats when an electrical current is passed through the unit. This causes a thermal injury to the disc material. This may result in injury to the smallest free nerve endings in the disc or end plates and help to relieve pain from disc degeneration. The treatment also may shrink the

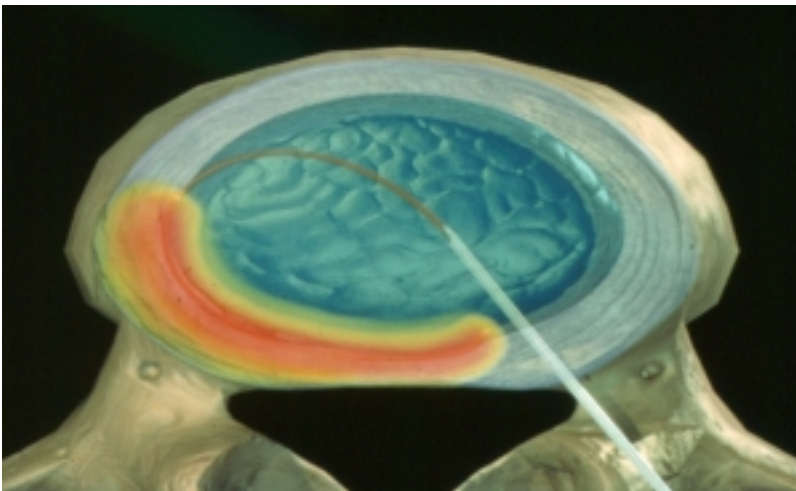
disc to a certain extent and help to alleviate pressure on a nerve causing sciatica. Our results have been consistent with the reported literature in that 50-70% of patients with single-level disc disease receive benefit. Patients with multi-level disease are less likely to receive benefit. The treatment appears to be extremely safe.

The Nucleoplasty procedure is an innovative device using radiofrequency energy to create an area of local tissue ablation and coagulation. These tissue changes occur at 40-70° C and minimize thermal damage to tissues. This device is introduced percutaneously under fluoroscopic control into the disc space. The tip of the device is advanced and withdrawn to create a "coblation channel" and reduce intradiscal pressure.

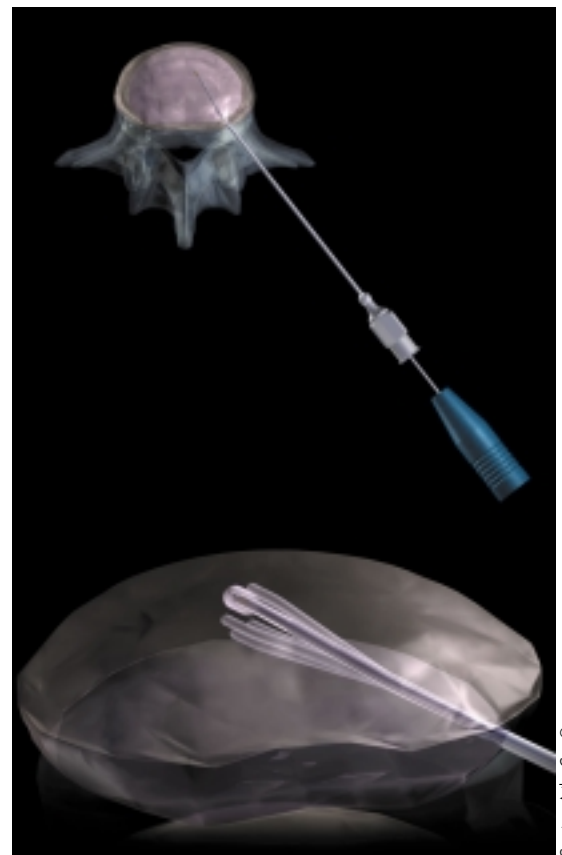
Both the IDET and Nucleoplasty devices are cleared for clinical use by the Food and Drug Administration. ■

### **IDET procedure:**

**A catheter with a thermal tip is inserted through the needle and is coiled in the disc. The catheter tip is heated for 15 minutes, and the assembly is removed.**



Courtesy ORATEC Interventions, Inc.



Courtesy ArthroCare®

▲  
**Nucleoplasty™ procedure:** With the guidance of x-ray images, the surgeon advances a needle into the disc. A specialized device known as a SpineWand™ is then introduced through the needle into the disc, (top image). Therapy consists of creating a series of channels in the disc and then thermally treating the tissue immediately adjacent to wand (bottom image).

## New hope for age-old problem: vertebral compression fractures

by Jonathan D. Sherman, MD and  
Peter C. Gerszten, MD, MPH

Osteoporosis is a disease that affects more than 24 million Americans. It results in progressive mineral loss from the bone and changes within the bony architecture, leaving the bones weakened structurally and therefore more subject to fractures.

There are an estimated 700,000 osteoporotic vertebral compression fractures in the United States each year. As many as one-third of these will become chronically painful. Eighty-five percent of these fractures are due to primary osteoporosis. These fractures can lead to progressive spinal deformity, causing changes in spine biomechanics contributing to increased risk of further fracture at adjacent levels or progressive malalignment, deformity, and pain. Mortality may be increased as much as 30% in patients with osteoporotic vertebral compression fractures.

Vertebral compression fractures secondary to osteoporosis usually occur after minor trauma or spontaneously. There is usually an acute onset of severe back pain. This back pain, depending on the severity of the fracture, can be mild to severely debilitating. Traditional treatment has been bed rest, pain medication and bracing. Reconstructive surgery has been traditionally reserved for patients with incapacitating pain or patients with loss of neurologic function. Surgery is considered an option of last resort, not only because vertebral compression fractures generally affect patients of advanced age, but also because of the high failure rates of reconstructive surgeries in patients with severe osteoporosis.

In addition to severe pain, vertebral compression fractures frequently cause malalignment of the spine. This has numerous consequences. Any change in alignment leads to abnormal biomechanical forces influencing the rest of the spine. This can lead to further malalignment of the entire spine. Malalignment puts unusual stresses on muscles, tendons, ligaments, and bones throughout the spine. Malalignment and pain can also lead to significant problems with balance or with walking ability and therefore reduce overall levels of activity. Decreased activity can lead to numerous additional medical problems.

Vertebroplasty, first described in 1987, involves the forced injection of a low viscosity polymethylmethacrylate cement into the closed space of a vertebral body. Once polymethylmethacrylate solidifies, it adds significant structural strength to the vertebral body. This added strength is very successful at reducing pain secondary to vertebral compression fractures.

Several problems exist with the vertebroplasty technique. First, the technique makes no attempt nor accomplishes any restoration of normal alignment of the spine. The polymethylmethacrylate hardens and stabilizes the bone in the abnormal configuration that exists after the fracture. Also, the injection of polymethylmethacrylate needs to be performed under high pressure to allow infiltration of the entire vertebral body with the cement.


This high-pressure injection can lead to extravasation or "leaking" of the polymethylmethacrylate out of the vertebral body, into spaces around the vertebral body including the spinal canal. Equally as concerning is the possibility that the polymethylmethacrylate could exit the vertebral body via the venous drainage of vertebral bodies and enter into the large veins returning blood to the heart and lungs. This has been described, and when it occurs, the polymethylmethacrylate can become lodged in the lungs and lead to pulmonary compromise and potentially death.

Kyphoplasty is a new technique recently described that involves an introduction of a cannula into the vertebral body followed by the insertion of an inflatable balloon. The balloon is inflated within the vertebral body. When the balloon is inflated, it creates a space within the center of the vertebral body for the injection of polymethylmethacrylate. In addition, the inflation of the balloon itself can also lead to some increase in the vertebral body height and therefore correction of the abnormal configuration of the vertebral body that existed as a result of the fracture. Recent reports reveal a high success rate using this technique.

In summary, vertebral compression fractures are a significant problem not only because of pain, but also because of significant medical complications that arise as a result. There is a significant increase in mortality after vertebral compression fracture. Kyphoplasty, although in its infancy as a procedure, appears to hold promise as a powerful minimally invasive tool in the treatment of the vexing disease of vertebral compression fractures. ■

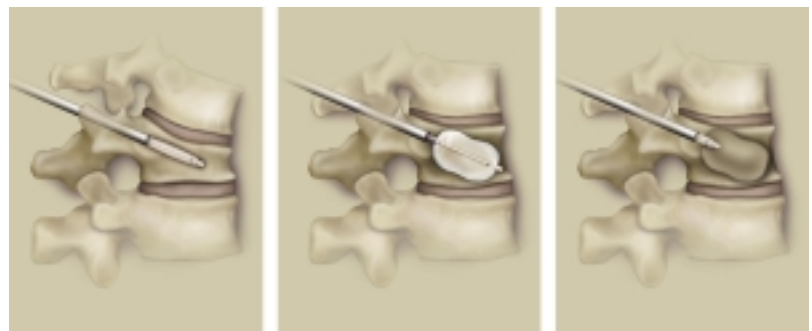


▲  
**Dr. Sherman**  
Visiting Instructor



▲  
**Dr. Gerszten**  
Assistant Professor  
of Neurological Surgery

▼  
**Kyphoplasty procedure.**



## Bone morphogenic proteins studied for use in spinal fusion

by William C. Welch, MD, FACS, FICS



▲  
**Dr. Welch**  
Director, Neurosurgical  
Spine Services

Spinal fusion is the joining of one vertebral body to another through bone ingrowth. Spinal fusion is performed to relieve pain due to spinal instability in conditions such as pars interarticularis fractures, spinal trauma, discogenic lower back pain or following tumor resection. Solid bone fusion is attempted in all patients undergoing fusion procedures but radiographic confirmation of solid fusion may occur in less than 75% of patients undergoing the procedures. Failure to obtain a solid fusion may result in persistent pain.

Successful fusion requires stable, immobile healing surfaces, a bony lattice (matrix) structure, osteogenic and osteoblastic activity. The immediate spinal stability is provided by internal fixation devices such as interbody fusion cages or pedicle screw fixation systems. The osteoblastic, osteogenic and matrix components have typically been provided by the addition of autograft bone obtained from the donor's iliac crest, frequently combined with allograft (bone bank) bone. Autograft bone has the advantage of containing live osteoblastic cells and growth factors required for osteoblastic and osteoinductive activity. These osteoblastic and osteoinductive proteins attract osteoblastic cells to the bone healing (fusion) site and stimulate the cells to produce bone.

Bone fusion is an extremely complex biologic process, and the sequence of events, the growth factors involved, their relative ratios and host factors promoting fusion are all undergoing active research. It is presumed that certain host factors such as smoking, obesity, diabetes mellitus as well as others retard bone healing, perhaps through microvascular changes. Bone fusion adjuncts, such as implanted bone growth stimulators or external bone growth stimulators augment the body's naturally occurring electrical signals which stimulate osteoblastic activity and subsequent bone growth.

Recently, proteins that have been shown to stimulate bone growth in animal studies have become available for clinical research. We are currently testing one material and expect to have two more studies underway in the first quarter of 2002. The first material is a bovine collagen-derived strip which is coated with blood obtained from the patient's iliac crest during anterior lumbar interbody fusion. This strip is used in lieu of the patient's own bone and does demonstrate osteoblastic and matrix activity.

Two more proteins will be tested shortly. The first protein is a true bone morphogenic protein grown in a mammalian cell culture system. This protein will be mixed with allograft bone and compared to autograft

bone alone in patients undergoing single level lumbar fusions performed without instrumentation. The second compound is a series of bone growth proteins that will be evaluated in patients undergoing posterior lumbar fusions with instrumentation. UPMC will be a leading test site for both materials.

The upcoming years may bring exciting new biologic products. These products may allow surgeons to fuse the lumbar spine using percutaneous, endoscopic, or minimally invasive techniques and still obtain fusion rates that exceed those currently reported. ■

---

### Minimally invasive spine surgery

(from page 1)

#### Minimal Access Lumbar Discectomy

The microdiscectomy procedure has been the "gold-standard" technique for unilateral disc resection. Improved technologies now provide a minimal access approach to this procedure. The minimal access, minimally invasive procedure involves localizing the disc space using fluoroscopy. A 1 cm paramedian skin incision is created and a series of dilation tubes are used to increase the opening so that a 2 cm access port may be secured in place. This access port provides a "tunnel" to the spinal canal. Microlaminectomy, discectomy and foraminotomy may be performed using any combination of techniques. The procedure may be supplemented with the use of endoscopes, microscopes or loupe magnification. The patients are routinely kept overnight and discharged the following morning.

#### Minimal Access Cervical Discectomy

Over the past 20-30 years, anterior cervical approaches have been used to address and correct disc rupture and spinal cord compression. Whereas anterior procedures usually require fusion across the disc space, posterior cervical microforaminotomy does not. The posterior cervical approach is similar to the lumbar microdiscectomy in that a small incision is created adjacent to the operative level and the extensor muscles are dissected off of the involved unilateral or bilateral lamina. Microlaminectomy, foraminotomy and discectomy is then performed depending on the clinical and radiographic presentation. Fusion is not routinely performed and the patients are usually discharged the following morning. Patients maintain their full range of cervical mobility and may be at reduced risk of accelerated disc disease at adjacent spinal levels. This technique is most applicable for patients with predominantly arm pain and associated neurologic findings. ■

### Satellite Office Opens at UPMC St. Margaret

The Department of Neurological Surgery has opened an outpatient office at UPMC St. Margaret offering patients a complete range of neurological services at the Fox Chapel facility. **Drs. Michael Horowitz, Joseph T. King, Jr., Douglas Kondziolka, L. Dade Lunsford, Donald Marion and John Moossy** will see patients at the office located in Suite 318 of the 100 Medical Arts Building.

The office is open on Fridays from 12:30 p.m. to 5:00 p.m. Appointments are available by calling (412) 647-4257. Patient consultations can be arranged by calling (412) 647-3685.

### Recent Grant Awards

- “Psychobiology of Suicidal Behavior in BPD,” **Dr. Anthony Fabio, PhD** (co-investigator) from National Institutes of Health (\$2,261,549). Study of the clinical, psychosocial and biological risk factors for suicidal behavior in patients with borderline personality disorder (BPD).

- “Quantitative Comparison and Validation of CT Perfusion Using Iodinated Contrast vs. Xenon CTBF in Human Stroke Patients,” **Dr. Howard Yonas** from General Electric Co. (\$25,000). Study to determine if CT Perfusion using iodinated contrast can provide accurate blood flow measurements in the management of stroke and other neurovascular conditions.

- “Radiosurgical Treatment of Temporal Lobe Epilepsy,” **Dr. Douglas Kondziolka** from National Institutes of Health (\$150,000). Study comparing two radiosurgical doses directed at the medial temporal lobe to standard medical therapy for epilepsy.

- “Image Fusion Technology,” **Dr. Amin Kassam** from Howmedica Leibinger, Inc. (\$75,000). Effort to develop an integrated neuro-navigation system using a microscope platform.

- “Isolation of Glioma Antigens from IL-4 Vaccine Patients,” **Dr. Hideho Okada, PhD**, from Doris Duke Charitable Foundation (\$324,000). Clinical trial of interleukin-4 (IL-4) gene transfected glioma cell vaccines hypothesizing vaccine will enhance the induction of a humoral immune response against glioma tumor-associated antigens.

- “Validation of Canine Venous Pouch Aneurysm Model by Comparison to Pathological Specimens of Human Intracranial Aneurysm,” **Dr. Amin Kassam** from Target Therapeutics (\$41,310). Study comparing canine venous pouch aneurysm model with human tissue harvested intracranial aneurysm specimens.

- “Treatment of Chronic Executive Deficits with AMH Following Pediatric Head Trauma,” **Dr. P. David Adelson** (co-investigator) from National Brain Injury Research Treatment and Training Foundation (\$95,560). Study to determine if treatment with amantadine hydrochloride (AMH) for frontal dysfunction is safe and effective.

- “Think First for Kids - FISA,” **Dr. Anthony Fabio, PhD**, from Federation of Independent School Alumnae (FISA) (\$153,497). Comprehensive brain and spinal cord injury prevention program focusing on classroom-based curriculum for children ages six to eight in city of Pittsburgh elementary schools.

### Media

- **Dr. Daniel Wecht** was featured in the *Pittsburgh Post-Gazette*’s “Dear Doctor” column October 30. Dr. Wecht addressed the significance of headaches as a warning sign of brain tumors.

- **Dr. P. David Adelson** was interviewed by Marilyn Brooks of WTAE-TV (Pittsburgh) on October 25 regarding his work with children with birth brachial plexus injuries.

### Announcements

- **Drs. A. Leland Albright, L. Dade Lunsford, Donald Marion and Ian Pollack** were all recently selected as one of “America’s Top Doctors” in a national survey conducted by Castle Connolly Medical Ltd.

- **Dr. C. Edward Dixon, PhD**, was elected president of the National Neurotrauma Society for 2002. Dr. Dixon was also granted tenure this past December.

- **Dr. Hideho Okada, PhD**, was promoted to assistant professor, tenure stream.

- **Dr. Jeffrey Balzer, PhD**, was promoted to associate professor.

### Notes

- **Dr. L. Dade Lunsford** served as Visiting Professor and Botterell Lecturer at the University of Toronto, November 26-27.

### New Employees

**Jocelyn Koessler**, clinical secretary for Drs. Howard Yonas and Donald Marion; **Melissa Persinger**, secretary to Dr. Ghassan Bejjani; **Kirkwood Gordan**, senior computer engineer for Dr. Robert Sclabassi; **Jill Dusak**, senior research specialist for Dr. Hideho Okada; **Daniel Santone**, researcher for Dr. P. David Adelson; **Kristen Hawn** project coordinator for Dr. Donald Marion; **Mary Hershk**, neurophysiology secretary, **Andrew Moyer**, neurophysiology tech; **Allison Toomey**, patient information coordinator. Welcome back to **Edie Ezykowsky**, secretary to Dr. El-Kadi.

### Congratulations

New baby boy (Hannon, October 15) to **Dr. Elad Levy** and wife Cynthia. New baby boy (Brendan, December 21) to **Patricia Kelly**, secretary to Dr. Peter Gerszten, and husband Tom.

### Upcoming Events

- February 6: **Dr. Vincent Traynelis**, professor of neurosurgery at the University of Iowa Hospital will speak as part of the department’s Visiting Professor Lecture Series. The lecture will take place at the Duquesne Club at 8:00 p.m. A reception and dinner will precede the lecture. Please contact Wendy Edwards at (412) 647-0990 for more information. ■



Department of Neurological Surgery  
University of Pittsburgh  
UPMC Presbyterian/Suite B-400  
200 Lothrop Street  
Pittsburgh, PA 15213  
(412) 647-3685

Douglas Kondziolka, MD, *Editor*  
Paul Stanick, *Production Editor*

Non-Profit  
Organization  
U.S. Postage  
**PAID**  
Permit #4166  
Pittsburgh, PA



*Pittsburgh Neurosurgery News* is written and published by the Department of Neurological Surgery at the University of Pittsburgh.

All content contained within this newsletter is copyrighted and is meant solely for the educational purposes of the reader. Please consult your physician before taking any medical actions or contact the Department of Neurological Surgery at (412) 647-3685. You can also e-mail us at [info@neuronet.pitt.edu](mailto:info@neuronet.pitt.edu).

You can download additional copies of *Pittsburgh Neurosurgery News* in Adobe .pdf format from our website at [www.neurosurgery.pitt.edu/news](http://www.neurosurgery.pitt.edu/news).



**Patient Referrals**  
**(412) 647-3685**

## *Clinical trials underway at the Department of Neurosurgery*

**Dose Escalation Study of LBS-Neurons Implanted into the Basal Ganglia of Patients Following Stroke.** Funded by Layton Bioscience, Inc. Contact: Dr. Douglas Kondziolka, (412) 647-6782.

**Evaluation of Durasis™ Dural Substitute as a Dura Mater Substitute.** Funded by Cook Biotech Incorporated. Contact: Dr. Ghassan Bejjani, (412) 647-9336.

**Hypothermia During Intracranial Aneurysm Surgery.** Funded by National Institutes of Health. Contact: Dr. Howard Yonas, (412) 647-6360.

**A Prospective, Randomized, Controlled Multicenter Clinical Study to Evaluate the Safety & Effectiveness of the COOLGUARD™ System with COOL LINE™ Catheter to Reducing Fever in Neurointensive Care Unit Patients.** Funded by: Alsius Corporation. Contact: Dr. Donald Marion, (412) 647-0956.

**Hypothermia for Severe Traumatic Brain Injury in Children.** Funded by National Institutes of Health. Contact: Dr. P. David Adelson, (412) 692-6347.

**The Optimal Management of Cerebral Aneurysms.** Funded by National Institutes of Health. Contact: Dr. Joseph T. King, Jr., (412) 647-0182.

**Radiosurgical Treatment of Temporal Lobe Epilepsy.** Funded by National Institutes of Health. Contact: Dr. Douglas Kondziolka, (412) 647-6782.

**Image Fusion Technology Systems.** Funded by Howmedica, Inc. Contact Dr. Amin Kassam, (412) 647-6354. ■

Learn more about the research programs underway at our department by visiting the research section of our website at [www.neurosurgery.pitt.edu/research](http://www.neurosurgery.pitt.edu/research).