



UNIVERSITY of PITTSBURGH **neurosurgery**news

Published by the University of Pittsburgh Department of Neurological Surgery ▼ ▼ ▼ www.neurosurgery.pitt.edu

Clip or coil? Randomized trial favors coiling for selected aneurysm patients

An October 2002 report in the British medical journal *The Lancet* supports the use of coiling — angiographic injection of platinum coils into the aneurysm to promote thrombosis — over clipping as first-line therapy in morphologically appropriate aneurysms.

The study — “International Subarachnoid Aneurysm Trial (ISAT) of Neurosurgical Clipping Versus Endovascular Coiling in 2143 Patients with Ruptured Intracranial Aneurysms: A Randomized Trial” — was so powerfully in favor of endovascular therapy that it was terminated early by the trial’s ethics committee which did not feel it could continue to offer surgery to patients that were candidates for less invasive therapy.

Current estimates show that 5% of the Western population harbors an intracranial aneurysm with rupture of the aneurysm occurring in six to eight per 100,000 persons. Once ruptured the risk of death or incapacitation is 60-70%.

Treatment has traditionally relied upon craniotomy and occlusion of the aneurysm using a metal clip that was placed across the opening of the aneurysm to seal its mouth.

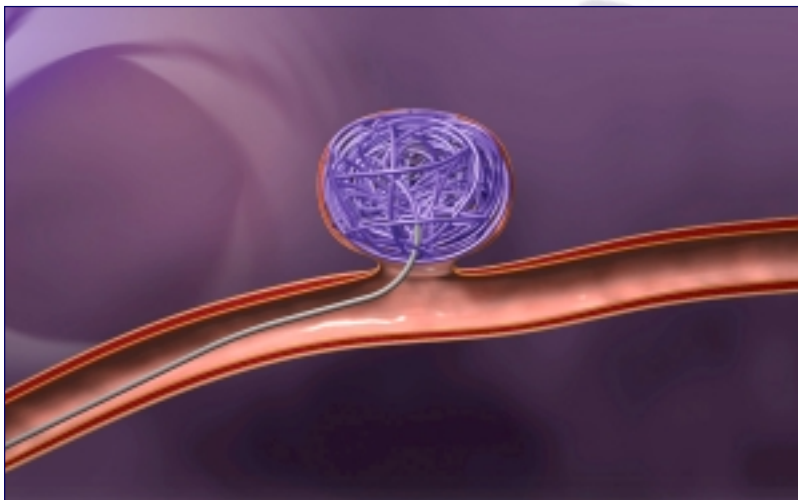
In 1990, Guido Guglielmi, MD, developed a less invasive procedure for treating such lesions. Guglielmi developed a platinum coil that could be placed through a catheter advanced through the femoral artery directly into the aneurysm. By filling the aneurysm with these

coils the lesion could be obliterated from within thus eliminating the need for open surgery. In 1995 this device was approved for use in the United States.

By 1999 the Department of Neurological Surgery at UPMC Presbyterian recognized the importance of the new field of endovascular surgery and its future role in the management of intracranial aneurysms along with other vascular diseases. Michael Horowitz, MD, a University of Pittsburgh trained neurosurgeon who had gone on to complete a fellowship training in endovascular neurosurgery at the University of Texas Southwestern Medical Center in Dallas, was recruited back to the Department of Neurosurgery to build an Endovascular Center of Excellence.

(see *study on page 4*)

Drawing of side wall aneurysm with coils inside the aneurysm dome.



Photos courtesy of Target Therapeutics, Inc

Coiling an aneurysm

by Michael Horowitz, MD

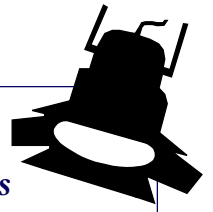
The GDC coil system provides the neurointerventionalist with the ability to percutaneously insert a coil into an aneurysm or blood vessel, assess its position, and withdraw it if the result is less than satisfactory. Other coiled systems are not detachable but rather pushed or injected into position. Once these coils leave the catheter they are difficult, if not impossible, to retrieve.

In order to treat an aneurysm with GDC coils, the interventionalist places a catheter into the carotid or vertebral artery using a femoral artery entry site. A 0.0018 inch or 0.0010 inch diameter microcatheter is then advanced through the first catheter and placed into the aneurysm fundus (dome).

Once the microcatheter is properly positioned, a coil is inserted through the catheter and into the aneurysm. If the operator does not like the coil’s configuration he or she can remove it and reposition it or choose another size coil.

The GDC system consists of a soft platinum coil soldered to a stainless steel delivery wire. When the coil is properly positioned within the fundus, a 1 or 2 mA current is applied to the delivery wire. The current

(see *detachable coils on page 4*)



Spotlight: Physician Assistants

PAs an important component in neurological services

Physician assistants are an important component to the neurosurgical services at the University of Pittsburgh. Our team of PAs is spotlighted below:



Kathleen Bissonette is a 1975 summa cum laude graduate of Alderson Broaddus College, Philippi, West Virginia. She has been with the department since 1986, joining Pediatric Neurosurgery at Children's Hospital of Pittsburgh in 1993. In 1995, she was awarded the Life Service Award by the Pennsylvania Society of Physician Assistants in recognition of her 11 years as the editor of the PSPA News and three years as the PSPA executive secretary.



Jeffrey Bost received his PA degree from Community College of Allegheny County and joined Dr. Joseph Maroon and his staff in June

1987. Bost has written or given 23 invited lectures, 24 national poster and oral presentations, 29 coordinated research projects, five workshops presentations, five articles and one book chapter. He is also a member of several UPMC Health System administrative committees and is a clinical instructor for Chatham College.



Douglas Clayton joined the department in January of 2001 after 13 years as a clinical laboratory scientist at UPMC. He received his

masters in Physician Assistant Studies from Chatham College. His research includes articles on transfusion requirements for patients with liver disease before and after liver transplantation.



Michael Habeck received his PA degree from Duke University in 1975 and joined the department in 1989. He is a former president

of the Pennsylvania Society of Physician Assistants and he recently received the society's Life Achievement Award. Habeck is also a PSPA liaison to the PA Department of Health and a current delegate from Pennsylvania to the American Academy of Physician Assistants.



Chrisanne Henicke graduated from Duquesne University in 1998. She joined the department in January 2001 after working with a team of internal medicine physicians in Washington, PA. Prior to establishing her career as a physician assistant, she worked as a research assistant at the University of Pittsburgh Department of Neurobiology.



Larry Marcello joined Dr. Maroon and his staff in July 1998 after thirteen years working in internal medicine and liver transplantation.

Marcello is currently coordinating clinical research projects and has participated in several national poster and oral presentations. He also is a clinical instructor for Chatham College and a captain in the Air Force Reserves. He received his physician assistant degree from the Community College of Allegheny County.



Robert Relic received his physician degree from Philadelphia University in 1999 and joined Dr. Maroon and his staff in 2001. He is

currently coordinating clinical research projects and has participated in several national poster and oral presentations. Relic is an ACLS Instructor, a licensed paramedic and clinical instructor for Chatham College.



Ed Shaffer is a graduate of the Seton Hill University physician assistant program. He has been with the department since August

2001. Prior to coming here he worked as a microbiologist at Canonsburg Hospital. While attending the University of Pittsburgh, Shaffer played on the 1995 Big East Championship baseball team.



Louisa Urgo has been with the department for five years after receiving her masters degree in Health Sciences from Quinnpiac College in

Hamden, CT in 1997. She has been involved in two papers and has a special interest in pain management. ■

Professors

- L. Dade Lunsford, MD
(Chairman)
- A. Leland Albright, MD
- Douglas Kondziolka, MD, MSc
(Vice Chairman, Education)
- Ian F. Pollack, MD
- Robert Sciabassi, MD, PhD
- Howard Yonas, MD
(Vice Chairman, Academic Affairs)

Associate Professors

- P. David Adelson, MD
- Jeffrey Balzer, PhD
- C. Edward Dixon, PhD
- Michael Horowitz, MD
- Larry W. Jenkins, PhD
- Donald Krieger, PhD
- John J. Moossy, MD
- Mingui Sun, PhD
- John K. Vries, MD
- William C. Welch, MD

Assistant Professors

- David Bissonette, PA-C, MBA
(Assistant Chairman/Executive Director)
- Eleanor B. Carson-Walter, PhD
- Donald J. Crammond, PhD
- Anthony Fabio, PhD
- Peter Gerszten, MD, MPH
- Glenn Gobbel, DVM, PhD
- Amin Kassam, MD
- Joseph T. King, Jr., MD, MSCE
- Ann H. Maitz, MSc
- Hideho Okada, MD, PhD
- Michael J. Rutigliano, MD, MBA
- Kevin Walter, MD
- Harold B. Weiss, MS, MPH, PhD

Clinical Professors

- Joseph C. Maroon, MD
(Vice Chairman, CMI Division)
- Peter Sheptak, MD
(Vice Chairman, Clinical Affairs)

Clinical Associate Professor

- Adnan A. Abla, MD
- Daniel A. Wecht, MD

Clinical Assistant Professors

- Ghassan K. Bejjani, MD
- Matt El-Kadi, MD, PhD

Research Professor

- Edwin Nemoto, PhD

Research Associate Professor

- John Herron, PhD

Research Assistant Professors

- Ronda Pindzola, PhD
- Ajay Niranjani, MCh

Research Instructor

- Wendy Fellows-Mayle, MA

Visiting Instructor

- Masaki Oishi, MD, PhD

Research Associate

- Xiecheng Ma, MD

Chairman's Letter: Dr. L. Dade Lunsford

Quo Vadis?

Our program continues to grow on an annual basis with a higher volume of surgical cases, challenging problems, and increased research productivity. Nationally, we are faced with a declining number of neurological surgeons practicing in the United States.

In the last five years, almost 700 neurosurgeons have stopped practicing, reducing the total number of practicing neurosurgeons to 2,500. This is a level last seen in 1990. What are the reasons for this decline in the number of neurosurgical practitioners both on a national as well as on a regional basis?

1. Despite dramatic changes in outcomes from neurosurgical intervention, the field remains challenging and occasionally stressful. New technologies continue to evolve, so that continuing medical education is always important. Our department has concentrated on a center of excellence model, bringing together the brightest and best neurosurgical providers, and allowing them to continue to set the pace for their respective sub-specialty fields. For this reason, we have specialists in pediatric neurosurgery, spine surgery, cranial base surgery, endovascular surgery, vascular neurosurgery, pain management, image-guided neurosurgery, movement disorders, epilepsy, and trauma. This core neurosurgical provider group is supplemented by an extensive research support team, an outcomes analysis group, and an extraordinarily productive clinical neurophysiology core who allow us to perform surgery more safely. Increasingly, neurosurgery is concentrated in such centers of excellence because of the resource support that is necessary to provide the highest level of patient care.

2. We are beset by increasing demands on our time for non-direct patient care related activities, including running the business and managing our compliance with health care regulations which continue to expand on a regular basis. Hours of specialty training are required to be aware of insurance provider and Medicare regulations, and now new training sessions for Occupational Safety and Health Administration (OSHA) and HIPPA are eminent. For those neurosurgeons who are involved in academic research, multiple web-based training modules are required to certify basic training in research techniques. These compliance requirements provide an additional burden on a neurosurgeon's time and availability.

3. Reimbursement for services continues to decline, and unless there is a revision in the CMS planned Medicare cuts due to come in effect in January, another 4.5% reduction in Medicare reimbursement will occur (on top of 5% last year). Other insurance plans follow suit. For this reason, neurosurgeons must continue to work harder and harder in order to maintain the same return.

4. In many communities, especially in Pennsylvania, adversarial trial lawyers provide a continuing challenge. The trial lawyers have maintained an enormously productive lobby, which supports many candidates for political office. At last, doctors have become better organized, with help from the regional Allegheny County as well as Pennsylvania Medical Societies. Many doctors have served noticed (to their representatives and members of

Congress) that they are "mad as hell and are not going to take it any longer." Physicians, having concentrated for the most part on their patient care concerns, have been poorly organized in the past.

Recently, surgeons in the northern West Virginia panhandle went on a "leave of absence" due to the prolonged malpractice stalemate in that state. No neurosurgeon currently practices in Wheeling. After the last left, he received a single-year malpractice bill of \$350,000.

In the Scranton area, orthopedic surgeons indicated that they would be unable to participate in trauma or new patient assignments. They cannot afford malpractice insurance even if it were findable.

We are losing surgeons continually in our area — low reimbursement and tort reform are cited as the major reasons. Governor-Elect Rendell's suggestion of a one time one year tax on the reserves of regional health insurers has already sent up howls of distress; it will almost certainly fail. A broad coalition of business leaders, insurance providers, consumers (previously called patients), and providers (previously called doctors) is needed to exact tort reform. It worked in California and Texas. Our state and region should be next.

Recently, a group of prominent regional physicians met with Senator Arlen Specter. He advised this group to concentrate their efforts on state tort reform by having caps placed on pain and suffering. This would require a constitutional change in Pennsylvania. An amendment must be passed twice by the state legislature in consecutive years, followed by a statewide referendum. This process, in short, would take a minimum of three years. By that time, Pennsylvania will have lost many neurosurgeons, ob-gyn physicians, orthopaedic surgeons and trauma surgeons who will no longer be able to afford to pay the current malpractice rates. It is to be hoped that faster action can be accomplished. Patients and physicians must band together to demand high quality health care and accountability.

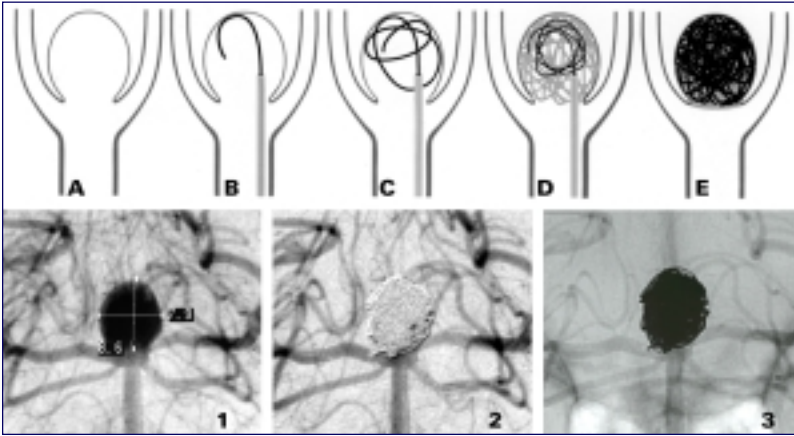
Already in Pennsylvania, many communities no longer have either ob-gyn, trauma or orthopaedic care. Emergency rooms are closing rapidly. In the past months, the UPMC Presbyterian Emergency Room has had a 20% increase in patient admissions. The hospital remains at a very high occupancy rate, and patients previously cared for in regional or community hospitals are now referred directly to academic medical centers. Our ability to provide this care is totally dependent upon infrastructure support. While this is building, we must allocate resources judiciously.

It is a paradox that as we expand our care of patients, as technologies flourish, and as outcomes show dramatic improvement, we are faced with the possible exodus of neurosurgical providers from western Pennsylvania. We're hopeful that we can force our legislators to act, and to restore balance. ■



Detachable coils offer neurosurgeon flexibility in treatment

(from page 1)



Top: A) aneurysm, B) microcatheter in aneurysm with coil being introduced; C/D) additional coils are introduced until aneurysm is completely filled; E) treated aneurysm. Bottom: 1) 8.6mm basilar apex aneurysm; 2/3) aneurysm postcoiling.

dissolves the stainless steel delivery wire proximal to the platinum coil by means of electrolysis. At the same time, the positively charged platinum theoretically attracts the negatively charged blood elements such as white and red blood cells, platelets, and fibrinogen thus inducing intra-aneurysmal thrombosis.

Once electrolysis occurs, the delivery wire can be removed leaving the coil in place. Another coil can now be introduced into the fundus. The process is continued until the aneurysm is densely packed with platinum and no longer opacifies during diagnostic contrast injections.

The mechanism by which GDC coils occlude aneurysms is still debated. We have made observations at surgery on coiled aneurysms that lead us to question the theory that the positive charge within the aneurysm during electrolysis induces significant thrombus formation.

Coils likely provide immediate protection against hemorrhage by reducing blood flow within the aneurysm sac, buffering arterial pulsations within the fundus, and sealing the weak portion of the wall or hole. Eventually organized thrombus does form within

Matrix™
polymer
coated coil



Courtesy Target Therapeutics, Inc

the aneurysm and the aneurysm is excluded from the parent vessel by the formation of an endothelialized layer of connective tissue that covers the neck's ostium. Mawad has demonstrated this in experimental dog models and in our own human autopsy studies.

The indications for GDC coils are continually expanding as interventionalists get more skillful in their placement and as newer coils are introduced into the market. The ultimate goal is that the majority of intracranial aneurysms will be treatable using this technique thus making craniotomy a procedure of historical interest only. Decisions concerning the application of GDC coils are made on a case-by-case basis and few dogmatic rules exist.

Matrix™ Detachable Coils

Further enhancing treatment options, doctors at the University of Pittsburgh are participating in a post-market clinical study evaluating Matrix™ Detachable Coils. These coils have a bonded polymer coating.

Compared to bare platinum coils, in pre-clinical animal studies, the Matrix™ coils accelerate the formation of intra-aneurysmal connective tissue, increase aneurysm neck tissue thickness and reduce aneurysm size. ■

Study recommends coiling

(from page 1)

Beginning in 1999 a large number of aneurysms were referred for endovascular therapy as Dr. Horowitz and vascular surgeon Dr. Amin Kassam began working together to determine which patients would best benefit from less invasive therapy. Since that time Drs. Horowitz and Kassam have treated aneurysm patients jointly and have found that approximately 70% of these lesions referred to their practice are good candidates for coil therapy.

Since 1999, Dr. Horowitz has coiled approximately 250 aneurysms over a 3-year period. Procedure related morbidity and mortality rates have ranged between 5 and 10% depending upon the lesion's location and morphology and only 1.5% of lesions have rebled since being treated.

In the study published in *The Lancet*, the relative and absolute risk reductions in dependency or death after allocation to an endovascular versus surgical treatment were 22.6% and 6.9% respectively. Thirty-one percent of patients were disabled or dead one year after surgery while 24% of endovascular patients suffered a similar fate. ■

Radiosurgery, resection, or observation for patients with acoustic neuromas: A survey of neurosurgeons' preferences

by Douglas Kondziolka, MD

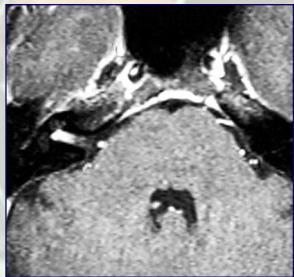Patients with acoustic neuromas have several treatment options including observation, surgical resection, stereotactic radiosurgery, and perhaps fractionated radiotherapy. Resection is indicated for patients with larger tumors which have caused major neurological deficits from brain compression. Surgeons perform stereotactic radiosurgery as primary treatment with the goals of preserved neurological function and prevention of tumor growth.

Many patients choose between radiosurgery and resection based on their own specific goals and their understanding of possible results. The decision can be difficult, and depends on the sources and strengths of information given to the patient. These include discussions with surgeons and other physicians, written material from peer-reviewed medical journals, handouts from support groups, internet based reports (of variable reliability), and discussions between patients.

We mailed a survey to members of the Congress of Neurological Surgeons in July 2002. Six hundred sixty-three surgeons responded to the survey (30%). Eighty percent of neurosurgeons surveyed had either performed radiosurgery on a patient with an acoustic neuroma or had referred a patient for neurosurgery (n=530). Each surgeon was asked to respond to two separate case presentations.

Question:

You are a 37 year-old neurosurgeon who presents with mild decreased hearing on one side. You have no tinnitus and no balance problems. Facial function is



normal. An MRI scan shows an intracanalicular acoustic neuroma and serial scans have shown a small amount of growth. Which management strategy would you choose for yourself — observation; surgical resection; stereotactic radiosurgery; fractionated radiotherapy?

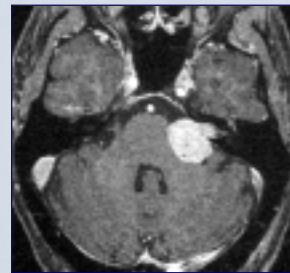
Response: A near majority of surgeons stated that they would choose stereotactic radiosurgery for management of their small acoustic tumor (n=283; 43%). Only 122 surgeons stated that they would choose surgical resection of their tumor (18%). Fractionated radiotherapy was chosen by 2% of responders. Interestingly, 240 surgeons stated that they would continue to observe their tumor (36%) rather than undergoing any

specific treatment at the present time. It had been stated in the case presentation that serial scans had already shown a small amount of growth. This tumor had been observed and was increasing in volume. Nevertheless, approximately one-third of responders continued to choose observation for a 37 year-old patient with a small, but growing tumor.

We evaluated the age of the responding surgeon and compared this to the treatment chosen by that surgeon. Across the age groups between 30 and 70 years, at least twice as many neurosurgeons chose radiosurgery for their tumor rather than resection. This was most pronounced in the younger surgeon age group (30 - 40 years), where four times the number of surgeons chose radiosurgery rather than resection. However, observation continued to be chosen by many. While one might think that an older person might choose radiosurgery over resection, simply to avoid the risks of general anesthesia or the surgical exposure, this did not necessarily appear to be true. This case reflected the care of an actual neurosurgeon who had gamma knife radiosurgery. He remains well 18 months following his procedure, and maintains a full practice. He has had no facial weakness or change in hearing.


Question:

You are a 50 year-old neurosurgeon who presents with mild decreased hearing on one side. You have tinnitus but no balance problems. Facial function is normal. An



MRI shows a left acoustic neuroma. Which management strategy would you choose for yourself — observation; surgical resection; stereotactic radiosurgery; fractionated radiotherapy?

Response: In this scenario, the neurosurgeon had a medium-sized acoustic tumor that indented the middle cerebellar peduncle but without compression of the fourth ventricle. The tumor measured 22 mm in the maximum diameter. The minority of surgeons recommended continued observation for a tumor of this size (6%). Surgical resection was recommended by 347 surgeons (52%), whereas radiosurgery was chosen by 261 surgeons (39%). Fractionated radiotherapy was only chosen by 3%. When the results were stratified by age, resection was the most popular choice across the groups between the ages of 30 and 60. However



▲
Dr. Kondziolka
Co-Director, Center
for Image-Guided
Neurosurgery

(see *acoustic* on page 6)

Brain tumor resection in awake patients may provide significant functional benefits



▲
Dr. Kondziolka
Co-Director, Center
for Image-Guided
Neurosurgery

by Douglas Kondziolka, MD

Brain tumors pose unique challenges for the patients who have them. These challenges are dependent upon patient age, tumor type, brain location, patient symptoms and other medical co-morbidities.

Most tumor surgeries can be performed under general anesthesia using computer-assisted navigation and with neurophysiologic monitoring. In some patients, particularly with tumors close to critical brain areas such as motor cortex or language cortex, performing tumor surgery while the patient is *awake* may have significant functional benefits.

The ability to test the patient's speech or strength while the brain is being exposed or while the tumor is being removed, allows the surgeon to maintain safety throughout the procedure. Should a deficit occur, the surgery can be stopped immediately so that any functional problem may hopefully be minimized.

Awake craniotomy has come a long way. With good anesthetic techniques, patients can be sedated with rapid acting medication such as propofol and remifentanyl.

Computer-assisted navigation allows the surgeon to accurately identify the position of the tumor before an incision is made so that the skin incision itself can be limited, and the bony exposure is as small as possible. The patient can be placed into rigid head fixation using a local anesthetic while under deep intravenous-based anesthesia.

When the dura is exposed, the patient can be rapidly awoken as the medications are reversed. The patient is told before the surgery that they will awake with their head unable to move and that we will provide a comfortable and quiet environment during this time.

In a recent surgery that involved a 38-year-old woman who had a small tumor in Wernicke's language

area, awake craniotomy was used to ensure that a good resection of the tumor could be obtained while preserving the patient's language function.

After exposure of the brain, electrophysiologic testing of the cortical surface showed no seizure activity or change in language function as the cortex was stimulated. The patient was able to speak and name objects presented to her on cards.

Once the regional cortex had been shown to be free of specific language functions, a cortical incision was made and the tumor exposed. She remained with excellent language function during this time. She was then placed into a deeper sleep in order to make her even more comfortable, and the rest of the tumor was evacuated.

She awoke rapidly after completion of the skin closure and felt well. Her speech was normal. Within 24 hours, she was ready for discharge. Such patients do not have to recover from the effects of a general endotracheal anesthetic.

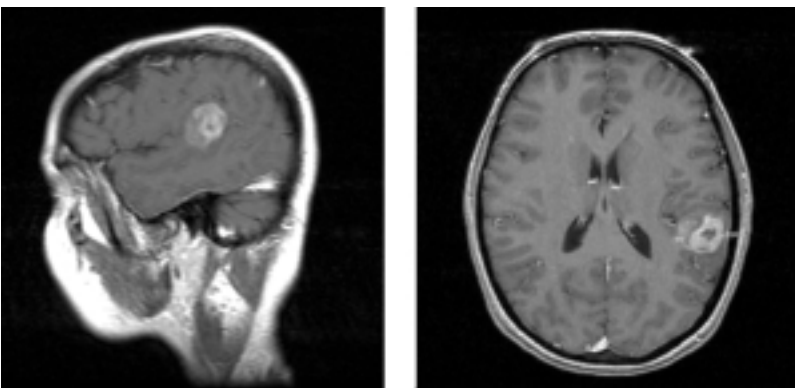
Awake craniotomy can be a useful tool for those patients with tumors best treated with resection and where the tumor is in a critical brain location. Together with colleagues in neuroanesthesia, neurophysiology, and neurology, this effective tool will improve further clinical outcomes with brain tumor patients. ■

Acoustic neuroma survey

(continued from page 5)

radiosurgery became more popular with advancing age of the survey group, passing resection as the most popular choice when the neurosurgeon is over age 60. It appears that surgeons chose to have a resection because of the larger volume of the tumor with indentation of the lateral surface of the brain stem. This patient was also a real neurosurgeon who had radiosurgery. He remains well 18 months after the procedure with a decrease in the size of the tumor. Facial function remains normal.

Patients with acoustic neuromas have several options available to them. Large tumors with significant brainstem compression usually require surgical resection. For patients with small or medium sized tumors, radiosurgery has become a common treatment with excellent long-term results reported. It is interesting to see how neurosurgeons themselves choose treatments as if they were the patient. ■



Sagittal and axial MR images showing a tumor in the left angular gyrus region near the Wernicke's speech area

Special Invitation

Dr. William Welch was a special guest of the Peoples Number Three Hospital in Wuxi, China this past November. The hospital invited him to perform and demonstrate two surgeries — a kyphoplasty and an anterior cervical discectomy with instrumented fusion using a bioresorbable plate. Both surgeries were “firsts” for this region. Guests from around China were invited to observe Dr. Welch perform these procedures. Dr. Welch also delivered two lectures at the Wuxi/Shanghai Spine Conference during his visit.

New Grant Award

• “Rapid Identification of Anti-Angiogenesis Gene Therapy Targets in Malignant Glioma,” **Dr. Kevin A. Walter, MD**, Elsa U. Pardee Foundation (\$75,000). Study, using bioinformatics and high throughput screening, to elucidate new genes associated with brain tumor angiogenesis and rapidly adapt these plans to potential therapies for malignant glioma.

Media

• **Dr. Joseph Maroon** was quoted in numerous local and national media outlets regarding his treatment of Pittsburgh Steeler quarterback Tommy Maddox following Maddox’s cerebral and spinal cord concussion sustained in a November 17 NFL game against the Tennessee Titans.

• **Dr. Harold B. Weiss, PhD** was mentioned in several media outlets regarding his paper on “pregnant women and motor vehicle crashes.” Outlets providing coverage included the *Pittsburgh Post-Gazette*, *Beaver County Times*, *Pittsburgh Courier*, WPXI-TV and KQV-Radio.



Awards

The *University of Pittsburgh Neurosurgery News* newsletter received honorable mention recognition for 2002 in the 37th Annual Exhibition of Western Pennsylvania printing awards. The newsletter was cited in the “Corporate & Business Communications House Organs” category. The awards are sponsored by the Printing Industry of Western Pennsylvania and recognize “excellence of achievement, effort and talent” for productions ranging from annual reports and capabilities brochures to creative die-cutting or pop-ups.

Study Shows Multiple Concussions Take Toll on Student Athlete

A high school athlete with a history of three or more concussions who sustains a new concussion may be up to nine times more likely to experience common symptoms than one with no history of concussion, according to a UPMC study published in the November issue of *Neurosurgery*.

The study — along with previous research — suggests that allowing enough time for the brain to heal and recover before a return to play is crucial in preventing more severe damage.

Sixty athletes with no prior concussion history were compared with 28 athletes with a history of three or more concussions. Investigators learned that the group with a history of three or more concussions was more than six times more likely to experience loss of consciousness; nearly four times more likely to have anterograde amnesia; and four times more likely to be confused. The odds ratio of retrograde amnesia between the two groups was not significant.

Welcome

Dr. Elle Carson-Walter, PhD, assistant professor of neurological surgery. Dr Carson-Walter will lead the department’s molecular biology core laboratory. Her research interests include the molecular mechanisms of tumor angiogenesis as well as the therapeutic manipulation of gene expression in malignancy.

Danielle Debranski, research nurse to Dr. P. David Adelson; **Virginia Corcos**, pediatric nurse practitioner; **Lorrie Robbins**, administrative assistant to Dr. Adelson; **Beth Arnold**, research assistant to Dr. Ian Pollack; **Loubov Mintas**, research assistant to Dr. Joseph King, Jr.; **Erin Ondrish**, research specialist to Dr. Adelson; **Debra Morris**, CIRCL administrative assistant.

Rebecca Roush, research assistant to Dr.

C. Edward Dixon; **Ramasri Sathanoori**, research assistant to Dr. Kevin Walter; **Robyn Bates**, senior computer engineer, Neurophysiology; **Michael Gielarowski**, research nurse to Dr. Dixon; **Patricia Karausky**, research nurse to Dr. William Welch.

Appointments

• **Dr. C. Edward Dixon, PhD** was named director of the Brain Trauma Research Center.

• **Dr. Harold B. Weiss, PhD** was named director of the Center for Injury Research and Control (CIRCL).

Congratulations

New baby boy (Lucas Garrett, December 11) to resident **Dr. Richard Spiro** and wife Paula.

Upcoming Events

• April 7-11: **Principles and Practice of Gamma Knife Radiosurgery**. Training course targeted at neurosurgeons, radiation oncologists and physicists interested in Gamma Knife certification. The next two courses are scheduled for June 2-6 and July 7-11. For more information, please contact Charlene Baker at (412) 647-7744.

• April 9: Visiting Professor Lecture Series. **Dr. Dennis D. Spencer**, Harvey and Kate Cushing Professor and Chair of the department of neurosurgery, Yale University. Duquesne Club, 6:00 p.m. For reservations, call (412) 647-0990.

• May 7: Visiting Professor Lecture Series. **Dr. Peter Carmel**, chairman of the department of neurological surgery at the University of Medicine and Dentistry of New Jersey (UMDNJ). Duquesne Club, 6:00 p.m. For reservations, call (412) 647-0990.

Department of Neurological Surgery
University of Pittsburgh
UPMC Presbyterian/Suite B-400
200 Lothrop Street
Pittsburgh, PA 15213
(412) 647-3685

Douglas Kondziolka, MD, *Editor*
Paul Stanick, *Production Editor*



Patient Referrals
(412) 647-3685



Non-Profit
Organization
U.S. Postage
PAID
Permit #4166
Pittsburgh, PA

Volume 4, Number 1

Winter 2003

Outcomes after coiling with anterior communicating artery aneurysms and paraclinoid aneurysms show promising results in two studies

One of the first reviews carried out by The Center for Endovascular Therapy at the University of Pittsburgh relating to aneurysm coiling related to the management of anterior communicating artery aneurysms. This study looked at 65 patients treated endovascularly for such lesions in Pittsburgh and Dallas from 1993-2002.

The ratio of ruptured to unruptured aneurysms was 57:8 with average aneurysm size being 6.3 mm. Procedure related permanent morbidity and mortality was 6% and 4.5% respectively.

Despite treating a large number of patients in very poor condition at the time of therapy, 63% improved or had no change

in exam after therapy. Complete aneurysm occlusion was 78% at a mean follow up of 10 months with another 16% achieving near complete occlusion. Re-bleed rate was 3% (two patients) one of which occurred in a patient with severe coronary artery disease necessitating high dose of anticoagulation therapy even after coiling.

A second review covered paraclinoid aneurysms. Between 1993 and 2002, 70 patients underwent coiling of such lesions in Pittsburgh and Dallas. Procedure related morbidity and mortality was 11.9% and 0%, respectively. Final outcomes at a mean follow-up period of 14 months showed 88.9% good recovery, moderate disability

in 3.2%, and severe disability in 1.6%. About 6.3% of patients died of unrelated causes during the follow-up period. Angiographic outcomes at a mean of 14 months showed complete occlusion in 87.8%, near complete occlusion in 6.1% and partial occlusion in 6.1%. No aneurysms re-hemorrhaged after coiling therapy.

These two studies, both of which have been submitted for publication, represent our attempt to better understand the role of endovascular therapy in the management of intracranial aneurysms. By studying our outcomes, we feel we can better advise patients as to their options when they present for therapy. ■

All content contained within this newsletter is copyrighted and is meant solely for the educational purposes of the reader. Please consult your physician before taking any medical actions or contact the Department of Neurological Surgery at (412) 647-3685.