

## Botulinum toxin impacts intraoperative monitoring for hemifacial spasm

**Miguel E. Habeych, MD, MPH**

*Assistant Professor of Neurological Surgery  
 Medical Director, Ctr for Clinical Neurophysiology*

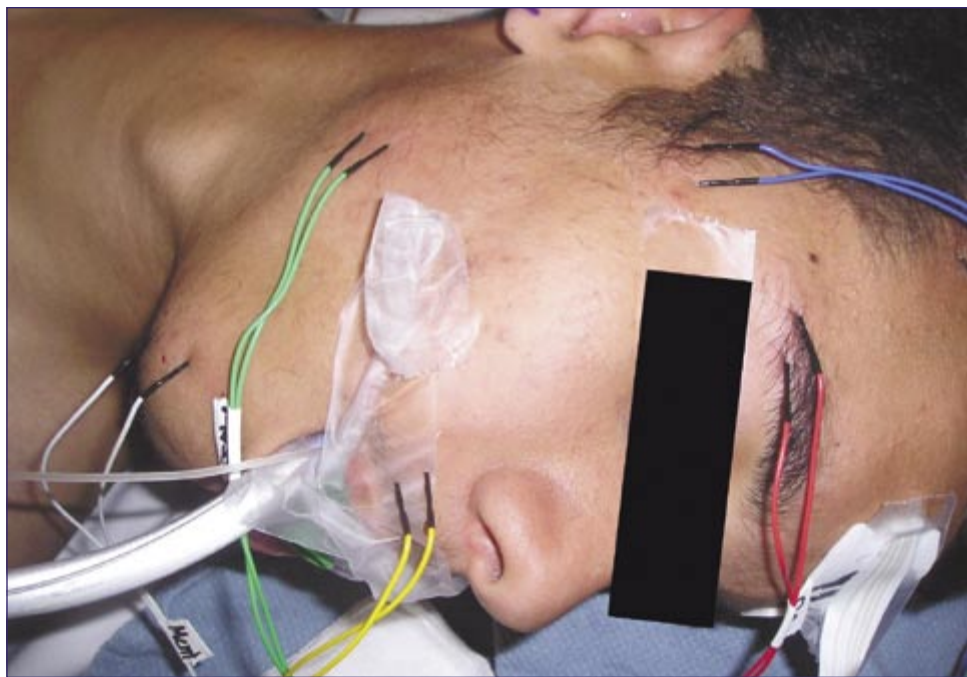**Jeffrey Balzer, PhD**

*Associate Professor of Neurological Surgery  
 Associate Director, Ctr for Clinical Neurophysiology*

**H**emifacial spasm (HFS) is a condition that manifests as intermittent involuntary twitching of the hemiface, usually beginning in the orbicularis oculi. Over time, there is progression to involve the entire major facial muscles on the ipsilateral side. The disease progresses becoming a socially disabling disease with no spontaneous recovery or even improvement that deteriorates the quality of life. Symptoms may be exacerbated by fatigue and stressful activities and although the intermittent spasm of the facial muscles is involuntary, voluntary movements such as talking and smiling also can trigger facial spasms.

Vascular compression is the most common etiology of spontaneous hemifacial spasm. A vessel of any size can cause the compaction with a broad range of severity that correlates with the intensity of the compression. Two hypotheses exist as to how vascular compression can result in hemifacial spasm. The first theory emphasizes the increased spontaneous activity and interaction that occurs among individual nerve fibers in the injured portion of the nerve. The second hypothesis assumes that the damage done to the facial nerve affects the facial motor nucleus in such a way that neurons in the nucleus are reorganized.

Treatment of HFS includes pharmacological approaches including Botulinum toxin injections, facial nerve denervation, and finally, surgical decompression from the offending vessel or vessels. Surgical decompression, termed microvascular decompression (MVD) was popularized at the University of Pittsburgh Medical Center (UPMC) and remains a routinely performed and highly successful approach to a number of cranial nerve disease states including HFS. An important aspect of both the pre-operative analysis of hemifacial spasm and the peri-operative surgical procedure is the utilization of neurophysiological monitoring. At UPMC, patients diagnosed by history and clinical examination with hemifacial spasm are referred to



**Patient undergoing MVD. Electrode placement allows for recording of EMG activity from multiple branches of the facial nerve, the trigeminal nerve and stimulation of the zygomatic branch of the facial nerve.**

the Center for Clinical Neurophysiology for neurophysiological testing. A routine battery of preoperative tests are performed including baseline brainstem auditory evoked potentials (BAEP's), and baseline "lateral spread" testing performed preoperatively for confirmation of an electrophysiological marker for HFS. Patients with HFS have a characteristic electrophysiologic anomaly termed the "lateral spread" response. In patients with HFS, when one branch of the facial nerve is electrically stimulated, not only do the muscles innervated by that branch display an evoked EMG response but other facial muscles not innervated by that branch also reflect EMG activity. This paradoxical "lateral spread" EMG response can be evoked continuously in the operating room, along with BAEP and spontaneous EMG recording, and be used as a guide for the MVD procedure.

During MVD for HFS, after the facial nerve is exposed and the offending vessel is lifted away from the facial nerve, the "lateral spread" response is typically observed to disappear within seconds of the decompression

(see image on page 3). This disappearance has a very high correlation with good clinical outcome in these patients, i.e., free of spasm postoperatively. Persistence of the response or a change in amplitude or wave morphology can indicate that there is an additional vessel impinging on the nerve and the exploration should continue. Interestingly, in the face of many patients receiving multiple Botulinum toxin injections prior to seeking surgery for their spasm, we have also found electrophysiological anomalies such that the lateral spread may not be as accurate an indicator of sufficient decompression.

Secondary to this observed Botulinum toxin phenomenon, we have investigated whether there is any difference in the neurophysiological manifestations, as well as, in the surgical outcome parameters of MVD to treat HFS, in patients who have previously received Botulinum toxin injections to treat their HFS. Two hundred and fifty (N=250) MVD's for HFS performed at UPMC, and monitored with

*(See Botulinum toxin on page 3)*

**Professors**

Amin Kassam, MD (*Chairman*)  
P. David Adelson, MD  
(*Vice Chairman, Research*)  
C. Edward Dixon, PhD  
Michael Horowitz, MD  
(*Chief of Neurosurgery,*  
*UPMC Presbyterian*)  
Larry W. Jenkins, PhD  
Douglas Kondziolka, MD, MSc  
(*Vice Chairman, Education*)  
L. Dade Lunsford, MD  
John J. Moossy, MD  
Ian F. Pollack, MD  
(*Vice Chairman, Academic Affairs*)  
Mingui Sun, PhD

**Associate Professors**

Jeffrey Balzer, PhD  
Peter Gerszten, MD, MPH  
Ajay Niranjani, MD  
Hideho Okada, MD, PhD  
Harold B. Weiss, MS, MPH, PhD

**Assistant Professors**

Dave Atteberry, MD  
David Bissonette, PA-C, MBA  
(*Executive Director*)  
Boyle Cheng, PhD, ScD  
Donald J. Crammond, PhD  
Johnathan Engh, MD  
Anthony Fabio, PhD  
Paul Gardner, MD  
Glenn Gobbel, DVM, PhD  
Paola Grandi, PhD  
Miguel Habeych, MD, PhD  
Adam S. Kanter, MD  
Arlan Mintz, MD, MSc  
David O. Okonkwo, MD, PhD  
Daniel Prevedello, MD  
Richard Spiro, MD  
Elizabeth Tyler-Kabara, MD, PhD

**Clinical Professors**

Adnan A. Abila, MD  
Matt El-Kadi, MD, PhD  
Joseph C. Maroon, MD  
(*Vice Chairman, Community Network*)  
Daniel Wecht, MD

**Clinical Associate Professor**

Michael J. Rutigliano, MD, MBA

**Clinical Assistant Professors**

Pedro Aguilar, MD  
Eric M. Altschuler, MD  
John R. Baker, MD, PhD  
John Bookwalter, MD  
Daniel M. Bursick, MD  
David J. Engle, MD  
David L. Kaufmann, MD  
Theodore J. Spinks, MD  
Parthasarathy Thirumala, MD  
Matthew Wetzel, MD

**Research Assistant Professors**

Yue-Fang Chang, PhD  
Wendy Fellows-Mayle, MA  
Hong Qu Yan, MD, PhD

**Clinical Instructor**

Jeff Bost, PA-C

**Research Associates**

Easter Jane, PhD  
Xiecheng Ma, MD

**Visiting Research Associate**

Easter P. Jane, PhD

**Chief Residents**

Karl Lozanne, MD  
Stephen Pirris, MD  
Martina Stippler, MD

# Intraoperative neurophysiologic monitoring essential

This issue highlights the utility of multimodality intraoperative neurophysiologic monitoring during a variety of neurosurgical procedures. Intraoperative neurophysiologic monitoring at UPMC is utilized to minimize neurological morbidity, guide operative procedures and localize anatomical structures, including subcortical targets, peripheral and cranial nerves and sensorimotor cortex. The use of monitoring helps guide the surgical team during dissection, resection of pathology and placement of instrumentation and medical devices. The specific goal of such monitoring is to identify changes in brain, spinal cord, and peripheral nerve function prior to the occurrence of irreversible damage. The intraoperative monitoring service at UPMC is managed and executed by the Center for Clinical Neurophysiology, a highly specialized, in-house group of neurosurgical faculty and technical personnel.

The use of intraoperative neurophysiologic monitoring at UPMC reaches across surgical disciplines and has proven invaluable not only in adult and pediatric neurosurgical procedures but also in orthopedic, ENT and cardiothoracic surgeries. Intraoperative multimodality monitoring at UPMC includes expertise in somatosensory evoked potential (SSEP), brainstem auditory evoked potential (BAEP), motor evoked potential (MEP), and electromyography (EMG) recordings. Direct peripheral nerve recordings also are performed for brachial plexus explorations and repairs as well as single unit micro-electrode recordings performed during placement of DBS electrodes in various subcortical structures. Intra-

operative EEG is also used to monitor cerebral function during carotid, vascular and cardiac procedures. In addition, EEG recorded directly from the pial surface, or electrocorticography (ECoG), is used to help determine resection margins for epilepsy surgery, and to monitor for seizures during direct electrical stimulation of the brain surface carried out while mapping cortical function in awake patients.

The Center for Clinical Neurophysiology has now grown to providing nearly 5,000 intraoperative monitoring cases per year at UPMC institutions. In addition to providing intraoperative monitoring services, the Center for Clinical Neurophysiology also performs diagnostic testing through its associated laboratories, transcranial Doppler and quantitative blood flow examinations, and continuous intensive care unit monitoring at UPMC intensive care locations.

We feel that the application of multimodality intraoperative neurophysiologic monitoring during a variety of peripheral and central nervous system operative procedures has and will continue to provide for an additional element of high-level care for our patients. The Center for Clinical Neurophysiology, its highly trained faculty and technical staff and the tools and techniques they utilize, bring yet another component of exemplary patient care to the UPMC patient population. •



**Amin Kassam, MD**

*Professor and Chairman*

*Department of Neurological Surgery*

*Director*

*Minimally Invasive endoNeurosurgery Center (MINC)*

## Some Key Clinical Phone Numbers

Clinical Neurophysiology.....	(412) 647-3450	Movement Disorders .....	(412) 647-7744
CyberKnife ( <i>spine</i> ) .....	(412) 647-1700	Neurotrauma .....	(412) 647-1025
CyberKnife ( <i>cranial</i> ).....	(412) 647-8312	Neurosurgical Oncology .....	(412) 647-8312
Endovascular .....	(412) 647-7768	Pediatric Neurosurgery .....	(412) 692-5090
Gamma Knife .....	(412) 647-7744	Referrals (General).....	(412) 647-3685
Minimally Invasive endoNeurosurgery		Spine .....	(412) 802-8199
Center (MINC).....	(412) 647-6778	Synergy.....	(412) 647-9786

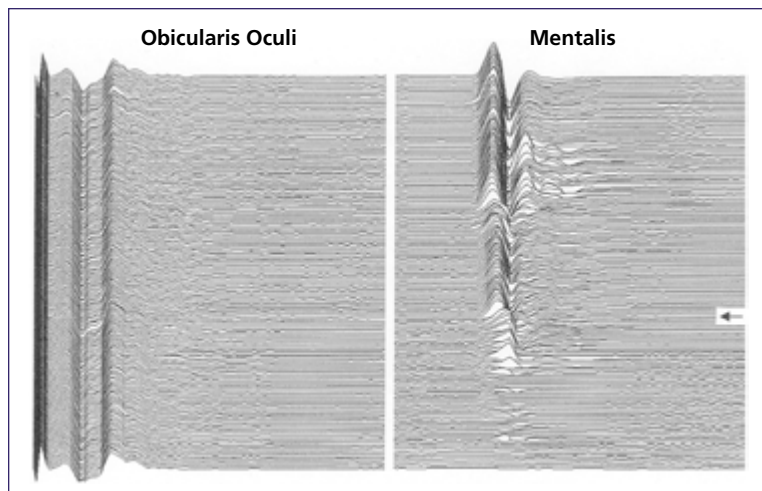
## Botulinum toxin and hemifacial spasm

(continued from page 1)

BAEP's, spontaneous electromyography and elicited "lateral spread" response, were retrospectively analyzed. Latency, amplitude, threshold to elicit, disappearance during, or persistence at the end, as well as capability to drive the "lateral spread" were considered as possible variables. Previous Botulinum toxin treatment was the grouping factor. Preliminary results show that lateral spread amplitude and latency significantly varied according to whether or not the patients had been treated with Botulinum toxin for their HFS before the surgical procedure. Lateral spread amplitude also varied significantly according to whether or not it was able to be driven at the end of the decompression. These findings indicate that "lateral spread" monitoring may be less sensitive in predicting the sufficiency of decompression of the facial nerve in patients who have undergone multiple Botulinum toxin injections.

Relevant to our findings and the hypothesis that receiving multiple, preoperative treatments with Botulinum toxin for HFS may impact MVD, is the fact that Botulinum toxin type A seems to preferentially affect hyperactive synapses, the same type as those involved on ephaptic transmission. Also, the chemodenervation produced by Botulinum toxin can result in muscle atrophy which, after discontinued use, can reverse after two to four months as the nerve re-innervates. During this period there could be potential consequences for multiple repeated injections, which, might serve to increase the nerve sprout network, with possible long-term, unwanted effects such as poly-innervation. This phenomenon may be responsible for the changes in "lateral spread" waveform morphology that we have found.

It is now routine to wait at least 6-9 months after the last Botulinum toxin treatment to operate on these patients anticipating that the lateral spread EMG response would be abnormal and not as accurate a predictor of outcome in these procedures. Because of this electrophysiological Botulinum toxin phenomenon, all patients having MVD for HFS less than nine months at UPMC undergo preoperative "lateral spread" testing to detect and characterize electrophysiological abnormalities prior to surgery. These practices have improved the success of using "lateral spread" intraoperative recordings to portend good clinical outcomes in this patient population. •



Recordings of the stimulus-evoked EMG responses from orbicularis oculi (left) and mentalis (right) muscles in response to stimulation of the zygomatic branch of the facial nerve. Note that upon decompression (arrow), the paradoxical lateral spread response (mentalis) becomes variable in amplitude and morphology and eventually disappears with no significant change observed from the oculi muscle group.

## The Center for Clinical Neurophysiology at the University of Pittsburgh

The Center for Clinical Neurophysiology, under the medical direction of Miguel Habeych, MD, MPH, provides a wide range of diagnostic and intraoperative neurophysiologic monitoring services designed to investigate and protect the function of the nervous system.

The Center for Clinical Neurophysiology (CCN) at the University of Pittsburgh Medical Center was organized in 1981 as an interdepartmental (Neurosurgery, Neurology, Anesthesiology, Orthopedics, Psychiatry and Pediatrics) resource integrated with all UPMC-affiliated health care institutions. The service has now grown to providing over 5,000 intraoperative monitoring cases per year at UPMC institutions alone.

In addition to providing intraoperative monitoring services, the CCN also performs diagnostic testing through its associated laboratories, transcranial Doppler and quantitative blood flow examinations, and continuous intensive care unit monitoring at UPMC intensive care locations. The CCN supports a full range of diagnostic tests such as all modalities of evoked potentials, computerized EEG acquisition, electromyographic studies, TCD evaluation, Xenon blood flow studies and neuro-otologic studies.

The CCN has the expertise to provide all types of intraoperative monitoring, including sensory evoked potentials, motor evoked potentials, direct nerve recording, electrocorticography, micro-electrode recording and language mapping and testing during awake craniotomy.

Currently, the CCN is composed of faculty from the Department of Neurological Surgery as well as a staff of over 20 CNIM certified technologists providing integrated intraoperative monitoring services across the entire UPMC health system.

The CCN has a comprehensive in house training program consisting of both hands-on training, intraoperative instruction and discussion with board certified clinical neurophysiologist and fellow technologists as well as a broad didactic lecture series taught by the faculty.

Additionally, a comprehensive and continuous quality assurance program ensures high-level and competent delivery of IOM services. The CCN faculty also participate regularly in undergraduate education at the University of Pittsburgh in the form of instructing an advanced level neuroscience course entitled "Foundations of Clinical Neurophysiology."

Services are delivered within the CCN via a multi-layered approach beginning with certified technologists working personally with board certified clinical neurophysiologists on site in the operating rooms coupled with continuous real-time remote oversight and interpretation by a team of physician neurologists. The entire team works closely with all surgical and anesthesia specialties and garners respect as an integrated team member providing exemplary patient care.

# Cortical, subcortical mapping permits aggressive resection of tumors

**Parthasarathy D. Thirumala, MD**

*Clinical Asst. Professor of Neurological Surgery*

The primary goal in surgery for intracranial tumors is to maximize resection while minimizing neurological deficits. This makes resection of tumors adjacent to the primary motor cortex in both hemispheres and primary language areas in the dominant hemisphere challenging. Cortical mapping of the language and motor areas by the neurophysiologist during awake craniotomy helps the surgeon tailor the tumor resection without causing a significant post operative neurological deficit. This procedure has recently gained national attention when a prominent politician and an actor from Hollywood had malignant gliomas resected adjacent to the language areas.

We have significantly advanced our knowledge of the language areas and pathways since first described by Paul Broca in 1861. We know that language areas reside in the dominant hemisphere of the brain with speech production in Brocas area (inferior frontal gyrus). Comprehension of language is located in the posterior part of the superior temporal gyrus (Wernickes area). The arcuate fasciculus is a subcortical connection between those two areas. Under less than optimal conditions the neurophysiologist performs language testing while the surgeon induces speech arrest with electrical current to map language areas.

The somatotopic organization of the primary motor and sensory cortices provides a physiological basis for mapping the cortical regions in both hemispheres. With increased understanding of the outflow connections from the cortex, mapping of the subcortical fibers in the tumor bed during resections is also very valuable in preservation of deep white matter sensory and motor pathways.

## Anesthesia considerations

Principles of anesthetic regimen during awake craniotomies have little changed since it was first described by Wilder Penfield in 1920. He stated that patients should be alert during electrical stimulation, and must read and talk when the surgeon is interfering with an area of cortex essential to speech. Anesthetic regimen during the surgery has evolved from “awake craniotomy” to “asleep-awake-asleep” craniotomy. The former includes local anesthesia for craniotomy with sedation or general anesthesia after language and motor testing.

With the advent of newer intravenous anesthetic medications including diprivan (propofol), remifentanil (ultiva), and more recently dexmedetomidine (precedex) “asleep-awake-asleep” technique is now widely used without the need for endotracheal intubation after tumor resection. This decreases the post-operative medical morbidity and decrease the length of stay. Children in general and some adult patients cannot tolerate this procedure awake and will have to have the resection surgery under general anesthesia.

## Cortical and subcortical mapping of language and motor areas

Successful mapping with motor and language testing in the operating room requires good preoperative evaluation of functional status. Preoperative language testing including speech, reading and simple mathematical calculations are done based on the location of the lesion. Facial and bilateral upper and lower extremity motor function is also documented preoperatively.

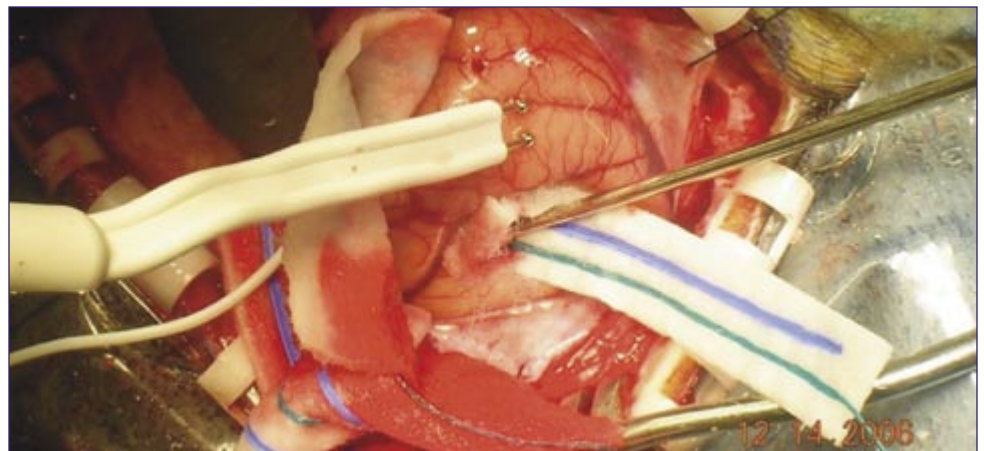
After a tailored craniotomy using image guidance the patient is woken up as part of the asleep-awake-asleep anesthetic regimen. An Ojemann cortical stimulator, which can deliver graded increases in biphasic current at a predetermined duration and frequency is used to stimulate areas in the brain. The stimulation parameters allow for adequate stimulation and minimize the potential to induce an intraoperative electrographic or clinical seizure. Potential for seizure activity is monitored by continuous electrocorticography using subdural grid electrodes thus eliminating the possibility that speech arrest is the result of seizures, and not due to cortical stimulation.

Speech arrest in response to cortical stimulation during an appropriate language task (positive cortical mapping) is used for language mapping. Speech difficulty from weakness in the facial and tongue muscles are evaluated by frequent neurological exams. Subcortical mapping of the arcuate fasciculus in the tumor bed following the cortical resection can reduce postoperative aphasia. More recently the absence of speech arrest (negative cortical mapping) has been shown to reduce the need for extensive craniotomy still permitting aggressive resection of the tumor without language deficits.

A clinical motor response, like moving the arm, can help identify the primary motor area during cortical mapping and avoid it during subsequent resection. Subcortical mapping of motor tracts when resecting tumors adjacent to precentral and deep insular regions preserve the corona radiate and in turn preserve motor function.

Tumors adjacent to other functional regions including primary sensory cortex (sensation), angular gyrus (calculation), supramarginal gyrus (spatial awareness), insula (language), and frontal eye fields, can be resected after cortical mapping. Significant recovery of function after removal of some of the areas is increasing our understanding of brain plasticity.

We believe that cortical and subcortical mapping of the cortical and subcortical language, and motor pathways permit aggressive resection of tumors while reliably decreasing the likelihood of postoperative neurological deficits. Increased acceptance of awake-asleep-awake anesthesia technique reduces the need for endotracheal intubation and decreases the length of stay in the hospital. •



**Direct cortical stimulation during language mapping. A bipolar stimulator is used for direct biphasic stimulation of the temporal lobe. Stimulation allows for mapping of language areas during awake craniotomy and resection procedures.**

# Somatosensory evoked potential (SSEP) monitoring reduces injury, complications in EEA

Parthasarathy D. Thirumala, MD

Clinical Asst. Professor of Neurological Surgery

**S**omatosensory evoked potential (SSEPs) monitoring during spinal surgery is well documented to prevent and reduce iatrogenic neurological injury. SSEPs are recorded from the spinal cord and the scalp following peripheral nerve stimulation in the arms or legs. The integrity of the spinal cord dorsal columns, brainstem medial lemniscal pathways as well as thalamus and its connections to the primary sensory cortex can be monitored with SSEPs during surgery. During a surgical procedure SSEP monitoring is also sensitive to changes in patient positioning of the neck, pressure on the brachial plexus, and peripheral nerves in the limbs.

Expanded Endonasal Approach (EEA) is a novel minimally invasive technique developed at UPMC that involves use of endoscope and complex neuronavigational systems with neurosurgery and otolaryngology working together during all phases of surgery. Using the principles of expanded endonasal approach we are able to access the entire ventral skull base, from the crista galli and up to and through the odontoid. Although minimally invasive, the EEA still carries a risk of potential injury to neurovascular structures including the internal carotid arteries, anterior cerebral artery, extraocular and lower cranial nerves. We believe that SSEP monitoring during the EEA can decrease the incidence of postoperative neurological deficit.

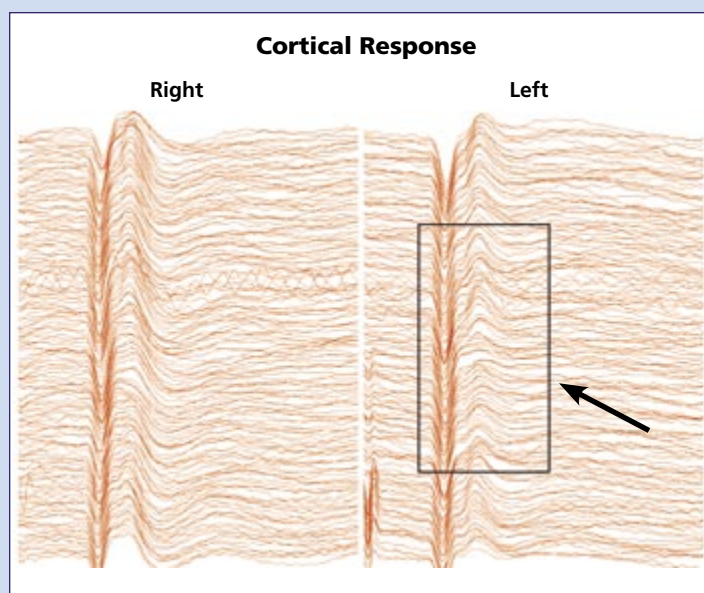
## Cerebral Hemodynamics and SSEPs

SSEP monitoring is used during intracranial surgeries to identify regional and hemispheric changes in cerebral blood flow during aneurysm surgery, and carotid endarterectomies. The cortical generators including the primary somatosensory cortex and thalamus receive blood flow from the anterior, middle and posterior cerebral arteries, respectively. Adequate cerebral blood flow is necessary for viable neuronal cells in the cerebral cortex to generate SSEP responses.

Normal cerebral blood flow is approximately 50ml/100g/min with higher requirements in the cortical regions and lower in the subcortical regions. A drop in cerebral blood flow below 15-20ml/100g/min causes a complete loss of the amplitude of cortical SSEP responses. However, the neuronal cells in the cortex are viable if there is a *reversible change* in CBF or if it does not drop to below 10ml/100g/min. Animal studies also support the notion that loss in neurophysiological responses is a precursor of ion pump failure at the cellular level. This implies that there is a narrow hemodynamic window where a *reversible change* in the amplitude of cortical SSEP responses does not imply loss of neuronal viability. Research at our institution on SSEP monitoring during conventional skull base surgery indicated patients with reversible SSEPs changes had reduced incidence of post operative neurological deficits. Hence we provide early warning alarms so the surgeon can readjust the neurosurgical procedure.

## Intraoperative monitoring technique

To date we have recorded SSEPs simultaneously from the upper and lower limbs continuously during approximately 1000 EEA procedures including exposure and closing. We stimulated the median



The highlighted area indicates a significant decrease in the amplitude of left cortical responses from the right upper limb in response to left carotid tear which was successfully repaired.

or ulnar nerve at the wrist and tibial or peroneal nerve at the ankle or at the head of the fibula respectively. SSEP recordings were obtained from the scalp and cervical region using subdermal needle electrodes.

A reduction in primary somatosensory cortical amplitude and or the cervically recorded, subcortical response by greater than 50% or prolongation of response latency by greater than 10% from baseline unrelated to changes in anesthesia were viewed as being significant, and the surgeon was informed. These criteria have been previously validated and agreed upon in the literature as being of optimal sensitivity and specificity for detecting iatrogenic injury to neurovascular structures.

## UPMC experience

Our experience at UPMC is based on a large database of over one thousand procedures with SSEPs monitoring during EEA. We observed reversible changes in SSEPs cortical responses in 2.5% of the cases (*above figure*). Reversible significant decrease in the amplitude of the cortical responses was seen bilaterally with decrease in mean arterial pressure. Unilateral significant reversible changes were observed with manipulation or injury to carotid artery. We were able to identify both unilateral and bilateral reversible changes and alert the neurosurgeon who then modified the surgical plan. There were no post operative neurological deficits in this subset of patients. In comparison to traditional skull base surgery there was a lower number of EEA cases with changes in SSEP cortical responses and more importantly no postoperative neurological deficits.

We believe intraoperative neurophysiological monitoring with SSEPs during EEA will provide important information to prevent and reduce impending catastrophic neurovascular injury. With increased practice of the novel minimally invasive endoscopic skull base surgery, SSEP monitoring can serve as an important learning tool for training surgeons and residents.

We advocate a comprehensive approach to neurophysiological monitoring during EEAs including somatosensory evoked potentials, spontaneous and triggered electromyography of the cranial nerves II-XII, brain stem auditory evoked potentials, and electroencephalogram depending on the location of the neural structures at risk. •

# CONGRESS OF NEUROLOGICAL SURGEONS 2008 ANNUAL MEETING

## Department well-represented at recent CNS annual meeting in Orlando, FL, September 20-25, 2008

The following is a list of courses, seminars and papers presented by department faculty at the recent Congress of Neurological Surgeons annual meeting:

### • General Scientific Sessions:

*Community of Neurosurgery: Evidence as a Source of Knowledge.* Presiding Officer: Getch CC. Moderators: Tatter SB, Golfinos JG.. Technology Moderators: Ali Chahlavi A, Jost SC. "What Every Neurosurgeon Needs to Know: Pediatric Neurosurgery," **Adelson PD.**

*Community of Neurosurgery: Translational Science as a Source of Knowledge.* Presiding Officer: **Adelson PD.** Moderators: Linskey ME, Ghogawala Z. Technology Moderators: Hadjipanayis C, Groff MW.

### • Practical Courses:

*The Kassam Scope, Endoscopic Skull Base Surgery.* Course Directors: Jimenez DF, Luciano MG. Faculty: Frazee JG, Nakaji P, **Kassam AB**, Gaab MR. (Presenting Lecture: "Is Skull Base Surgery Changing to Minimally Invasive?" **Kassam AB**).

*Inpatient and Outpatient Management Dilemmas: For Nurses, APRNs and Physician Assistants.* Course Directors: Shaffrey ME, Strayer AL. Faculty: Mummaneni PV, Shaf-

frey CI, **Okonkwo DO**, Dumont AS, Jane JA, Sr, Elias WJ, Farace E, Lisman T.

*Operative Colloquium: Masters of Neurological Surgery.* Course Directors: Chandler WF, Awad IA. Faculty: Rezai AR, Gutin PH, Rosenwasser RH, Resnick DK, **Kassam AB.** (Presenting Lecture: "Is Skull Base Surgery Changing to Minimally Invasive?" **Kassam AB**).

*Spinal Radiosurgery.* Course Directors: **Gerszten PC.** Faculty: Angelov L, Bilsky MH, Chang SD, Henderson FC, Sheehan JP.

### • Luncheon Seminars:

*Anterior vs. Posterior for Cervical Radiculopathy.* Moderator: Theodore N. Faculty: Douglas AF, Khoo LT, **Maroon JC.**

*Intraventricular Endoscopy.* Moderator: Cohen A. Faculty: Avellino AM, Cavalheiro S, **Kassam AB.** (Presenting Lecture: "Intra-Axial Endoport Surgery: A Parafascicular Approach to Deep-Seated Lesions and Ventricular Tumors," **Kassam, AB**).

*Radiosurgery: What the Literature Supports.* Moderator: Pollock BE. Faculty: Isabelle M. Germano IM, Golfinos JG, **Kondziolka D**, Sheehan JP.

### • Section Seminars:

*CNS Neurosurgical Forum: Section on Neurotrauma and Critical Care.* Moderators: Ullman JS, Timmons SD. "Levetiracetam versus Phenytoin as Seizure Prophylaxis In Severe Traumatic Brain Injury," **Jones KE**, **Puccio AM**, **Harshman KJ**, Falcione B, Benedict N, **Jankowitz BT**, **Fischer M**, **Sauber-Schatz EK**, **Fabio A**, **Darby JM**, **Okonkwo DO.**

*Section on Neurotrauma and Critical Care Seminar. Injury Prevention: Neurosurgery and Public Health.* Moderators: Fehlings MG, Harris O. "Making Sports Safer," **Maroon JC.**

### • Presentations, Abstracts, Posters:

*Assessment of the Reliability of the Enneking and Weinstein-Boriani-Biagini (WBB) Classifications for Staging of Primary Spinal Tumors.* Chan P, Boriani S, Fournay

DR, Fehlings MG, Biagini R, Dekutoski MB, Ryken TC, Vrionis FD, Harrop JS, Schmidt MH, Vialle LR, **Gerszten PC**, Rhines LD, Ondra SL, Gokaslan ZL, Pratt SR, Fisher CG.

*Clinical and Radiological Outcomes of Non-vestibular Schwannoma Radiosurgery.* **Niranjan A**, **Kano H**, Kim IY, **Kondziolka K**, **Lunsford LD.**

*Comparison of Test Methods for Posterior Cervical Implant Characterization: Bench Top and Biomechanical Human Cadaveric Flexibility Protocols.* **Cheng BC**, **Pirris SM**, Cook D, **Kanter AS**, Welch WC.

*Endoscopic Endonasal Skull Base Reconstruction with a Vascularized Nasoseptal Flap for a Giant Anterior Fossa Encephalocele.* **Prevedello D.**

*Evaluation of Single Fraction Spine Radiosurgery Using Cone Beam CT Image Guidance.* **Gerszten PC**, Flickinger JC, Quader M, Novotny J, Huq S.


*The Front Door to Meckel's Cave: An Antero-Medial Corridor via Expanded Endoscopic Endonasal Approach. Technical Considerations and Clinical Series.* **Prevedello D.**

*Gamma Knife Radiosurgery for Intraventricular Meningiomas.* Kim IY, **Kondziolka D**, **Niranjan A**, Flickinger J, **Lunsford LD.**

*Integrated Medical Learning: Concepts and Outcomes from the 2007 CNS Meeting.* **Kondziolka D**, Asher A, Selden N, Rodts G.

*International Collaboration of Enterprise Stent-Coiling (ICES): Initial Results.* Mocco J, Snyder KV, Albuquerque F, Bendok BR; Boulos AS, Carpenter JS, Fiorella D, Hoh BL, Howington JU, **Jankowitz BT**, Liebman KM, Rai A, Rodriguez-Mercado R, Siddiqui AH, Veznedaroglu E, Hopkins LN, III, Levy EI.

*Management of Low Back-pain in Division I College Football Players: A Multi-institutional Study on Long-term Outcomes, Disability and Return to Play.* Jagannathan J, **Kanter AS**, Liu CY, Mills J, Sheehan JP, Williams BJ,



# IRGEONS TING

ber 20-25

Sheehan J, Maroon JC, Shaffrey CI, Bailes JE, Jane JA, Sr.

*Meningiomas of the Anterior Skull Base Resected Via an Endonasal Endoscopic Approach: Outcomes and Complications.* Tomycz ND, Prevedello DM, Gardner PA, Stefkó ST, Delfyett WT, Snyderman C, Carrau R, Horowitz MB, Kassam AB.

*Outcomes after Stereotactic Radiosurgery for Intracranial Hemangioblastomas: Sporadic Tumors and von Hippel Lindau Disease.* Kano H, Niranján A, Kondziolka D, Flickinger J, Lunsford LD.

*Outcomes Following Stereotactic Radiosurgery for Cancer that Invades the Cavernous Sinus.* Kano H, Kondziolka D, Niranján A, Flickinger J, Lunsford LD.

*Optimizing Radiosurgery for Acoustic Neuromas: the Quest for Hearing Preservation.* Kano H, Kondziolka D, Flickinger JC, Lunsford LD.

*Plasma Disc Decompression Compared to Fluoroscopy-guided Transforminal Epidural Injections for Symptomatic Contained Lumbar Disc Herniation: A Randomized, Controlled Trial.* Gerszten PC, Bhagia SM, Covey CM, Ford WJ, Huston CW, Kabazie JA, Mocek CK, Pino CA, Rathmell JP, Reusswig PN, Schultz DM, Simopoulos TT, Smuck MW, Tarver JM.

*Recent Advances in the Management of Childhood Brain Tumors: Have We Made a Difference?* Pollack IF.

*Section on Neurotrauma and Critical Care: Select Abstract Session.* Moderators: Tsai E, Okonkwo DO.

*Shallow Sella Syndrome.* Prevedello D.

*Should Younger Patients with Vestibular Schwannomas have Radiosurgery?* Lobato J, Zorro O, Kondziolka D, Kano H, Flickinger J, Lunsford LD.

*Utilizing Differential Mitochondrial Concentration between Glioblastoma and Normal Brain as Strategy for CNS Protection.* Mintz AH, Huang Z, Jiang J, Kagan VE. •

## Media Appearances

• **Theodore Spinks, MD**, was interviewed on KDKA-TV *TV News* (Pittsburgh), August 20, and WTAE-TV *Action News* (Pittsburgh), August 25, discussing research studies showing that cheerleading now accounts for two-thirds of the serious injuries reported among female athletes.

• **Amin Kassam, MD**, was featured in the October issue of *Pittsburgh Professional Magazine*. The article, entitled ‘Odyssey,’ described Dr. Kassam’s emigration from Uganda to his efforts today to develop a better form of brain surgery.

## Congratulations

• **Joseph Maroon, MD**, finished 19th in his division in the Hawaiian Ford Ironman World Championship Triathlon held October 11 in Kona, Hawaii. Dr. Maroon finished with a time of 15 hours, 57 minutes and 20 seconds. The event—one of the most recognized endurance events in the world—consists of a 2.4 mile ocean swim, a 112 mile bike race and a 26.2 mile run.

• **P. David Adelson, MD**, began his term as president of the Congress of Neurological Surgeons. Dr. Adelson’s term will run through the group’s annual meeting in New Orleans, LA, October 24-29, 2009.

• **L. Dade Lunsford, MD**, served on the Final Review Committee for grant allocation by the Deutsche Forschungsgemeinschaft September 29-30 in Berlin, Germany.

• **Julie Martin** was selected ‘Patient Ambassador’ for the month of September by the UPMC Physician Services Division.

• **Dr. Kassam** was recognized as a charter member of the International Meningioma Society.

• Medical students **Steven Addo-Yobo, Nikesh Anumula, Matthew Durst, Lily Hsieh, Deborah Jacobson, Mithulan Jegapragasan, Philip Lee, and Veronica Ortiz** completed their summer research program within the department. Anumula, Hsieh and Lee received the dean’s Certificate of Merit Award for their work.

## Prominent Lectures

• **Peter Gerszten, MD**, was a guest lecturer at the David C. Pratt Cancer Center of St. John’s Mercy Medical Center in St. Louis MO, on October 30.

• **Dr. Kassam** was an invited lecturer at the International Congress on Meningiomas and Cerebral Venous System in Boston, MA, on September 4. He was also an invited lecturer at the International Congress of the World Federation of Skull Base Societies & Annual Meeting of the North American Skull Base Society, in Vancouver, Canada, on September 11.

## Promotions

• **Tracy Wiles** was promoted to office coordinator, and **Keri Mills** was promoted to senior administrative assistant, both at UPMC Mercy.

## New Employees

• **Oren Berkowitz, Shannon Brandfass** and **Damarius Gomez**, all physician assistants; **Toni Morgan**, UPMC Mercy medical secretary; **Giamarie Zagacki, RN** for David Atteberry, MD; **Pamela Harper**, medical secretary for Pedro Aguilar, MD; **Kim Tonet**, executive secretary for Drs. Gerszten, Moossy, and Kanter; **Jennifer Seelman**, medical records clerk.

## Personal Congratulations

**Kristin Thompson**, and husband Roy had a baby boy (Finn James) on August 28; **Brian Jankowitz, MD**, and wife Rachel had a baby girl (Kathleen Grace) on August 26; **Matthew Maserati, MD**, was married to Megan Jones on August 16; **David O. Okonkwo, MD, PhD**, and wife Quirine had a baby boy (Steven Augustus) on July 25.

## Stuart Rowe Research & Lectureship Day Set for December 10.

The fourth annual Stuart Rowe Society Research & Lectureship Day, showcasing research activities in the field of neurological surgery, has been set for December 10. **Patrick J. Kelly, MD**, former chairman of neurosurgery at New York University’s Langone Medical Center and noted expert in computer-assisted stereotactic neurosurgery, will be the honored guest. Please call (412) 647-0990 for more info. •

Department of Neurological Surgery  
University of Pittsburgh Medical Center  
UPMC Presbyterian/Suite B-400  
200 Lothrop Street  
Pittsburgh, PA 15213  
(412) 647-3685  
neuroinfo@upmc.edu

[www.neurosurgery.pitt.edu](http://www.neurosurgery.pitt.edu)



Patient Referrals  
(412) 647-3685

Non-Profit  
Organization  
U.S. Postage  
**PAID**  
Permit #4166  
Pittsburgh, PA



University of Pittsburgh Medical Center  
Recognized as an honor roll member of *U.S. News & World Report's* 'America's Best Hospitals' 2008

FALL 2008 • VOLUME 9, NUMBER 4

## Gerszten co-authors first-ever book of its kind on spine radiosurgery

**P**eter C. Gerszten, MD, MPH, associate professor of neurological surgery and radiation oncology at the University of Pittsburgh, has co-edited the first-ever book of its kind on spine radiosurgery. The 119-page, 18-chapter book, *Spine Radiosurgery*, just released by Thieme Medical Publishers, covers a wealth of topics in this fast-breaking field and is co-edited by Samuel Ryu, MD, director of radiosurgery at the Henry Ford Health System in Detroit, MI.

With contributions from leading experts from the fields of neurosurgery, radiation oncology, medical physics, as well as medical oncology, the book is described by the publisher, "as the definitive reference for clinical applications of state-of-the-art radiosurgery of the spine. It discusses the benefits as well as the limitations of current spine radiosurgery treatments for benign and malignant spine disorders, primary and metastatic tumors, and spinal cord arteriovenous malformations."

Other contributors from the University of Pittsburgh Medical Center include Boyle C. Cheng, PhD, assistant professor of neurological surgery, Steven A. Burton, MD, associate professor of radiation oncology, and Cihat Ozhasoglu, PhD, assistant professor of radiation oncology.

Dr. Gerszten, a pioneer in the field of spine radiosurgery, is director of percutaneous spine services in the University of Pittsburgh Department of Neurological Surgery and leads the department's spine radiosurgery program. His clinical interests include minimally invasive approaches to the treatment of spinal disorders and spinal tumors. Dr. Gerszten also directs the instruction of this developing area of neurosurgery through practical clinics in conjunction with the annual meetings of the American Association of Neurological Surgery as well as the Congress of Neurological Surgeons. •

