

Accreditation Statement

The University of Pittsburgh School of Medicine is accredited by the Accreditation Council for Continuing Medical Education (ACCME) to provide continuing medical education for physicians.

The University of Pittsburgh School of Medicine designates this enduring material for a maximum of 0.5 AMA PRA Category 1 Credits™. Each physician should only claim credit commensurate with the extent of their participation in the activity. Other health care professionals are awarded 0.05 continuing education units (CEU), which are equivalent to 0.5 contact hours.

Disclosures

Drs. Gross, Jadhav, Jovin, and Jankowitz have reported no relationships with proprietary entities producing health care goods or services.

Instructions

To take the CME evaluation and receive credit, please visit UPMCPPhysicianResources.com/Neurosurgery and click on the course *Neurosurgery News* December 2016.

At the Cutting Edge of Stent-Assisted Aneurysm Coiling: UPMC and the Atlas Study

by **Bradley Gross, MD, Ashutosh Jadhav, MD, PhD, Tudor Jovin, MD, and Brian Jankowitz, MD**

Cerebral aneurysms may be incidentally discovered in up to 1-2% of the population. While part of the art of managing incidentally discovered aneurysms is selecting those for treatment, a more considerable challenge is selecting the safest and most effective treatment approach.

Numerous studies have reinforced the relative safety of minimally invasive, endovascular treatment of cerebral aneurysms as compared to traditional open microsurgical approaches. Most often, platinum-based coils can be detached and used to fill an aneurysm dome. However, the geometry of an aneurysm can serve as a relative limitation for coiling, as coils may herniate into the parent vessel of wider-based aneurysms, creating a potential risk of stroke. To address this limitation, an endovascular approach may utilize a stent to buttress the coil mass, keeping it in the aneurysm. Studies have shown that the usage of stents to assist aneurysm coiling also allows for greater coil packing density in the aneurysm and lower rates of aneurysm recurrence.

Intracranial stent technology has evolved considerably over the past 20 years. This began with the extrapolative use of coronary stents in the intracranial circulation. The first FDA-approved stent for usage in the intracranial circulation was the Neuroform™ stent. However, early stent technology had technical limitations. Stent deployment could be particularly nuanced or even unfeasible. In addition, relatively large microcatheters were needed to deliver the stent, at times limiting the

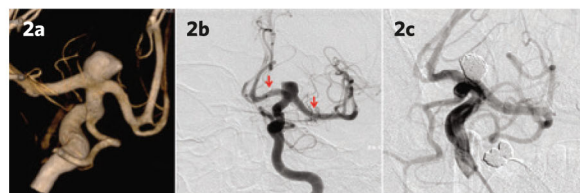


Figure 2. 3-D angiographic image of an aneurysm prior to treatment (2a). Angiogram after deployment of an Atlas stent (2b; arrows denote ends of the stent). Angiogram after coiling and completing treatment of the aneurysm (2c).

feasibility of stenting in relatively challenging locations or through smaller vessels. After multiple iterative improvements in stent technology, the Neuroform stent's successor, the Atlas™ stent, is being evaluated in trial form. The Atlas stent has multiple potential new design advantages. It is easier to deliver than traditional intracranial stents and can be delivered through smaller, easier to navigate microcatheters. Its unique hybrid design may allow for it to serve as a superior stent scaffold at the base of an aneurysm (see Figure 1).

Brian Jankowitz, MD, assistant professor of neurological surgery at the University of Pittsburgh and co-director of UPMC's Center for Endovascular Therapy, is principal investigator for the Atlas study. In this multicenter study, the new Atlas stent is being evaluated in a prospective, open-label study for efficacy in aneurysm occlusion and multiple secondary endpoints, including technical success, retreatment, and complications. One of the top site enrollers for the study is UPMC, where the Atlas stent has already been utilized successfully in multiple patients (see Figure 2). Initial results are promising, and we are pleased to be a large contributor to the next frontier in endovascular aneurysm treatment.



Figure 1. The Neuroform Atlas stent.

Free Online CME

To take the CME evaluation for this issue, visit our education website: UPMCPPhysicianResources.com/Neurosurgery.

Chairman's Message

Constant Change



Neurovascular lesions are common pathologies that can result in devastating neurological damage, including death. Over the past 25 years, our approach to managing these often challenging lesions has radically changed. In this issue of *Neurosurgery News*, we present some recent advances in this field. Understanding the risks and benefits of treatment versus observation of these lesions is key to their management.

When managing an incidental or minimally symptomatic lesion, the primary decision is to determine if treatment is safer than conservative observation. In order to make an informed decision, both approaches must be weighed. Accurately understanding the natural history of these neurovascular lesions is helpful in determining the risk associated with observation versus treatment. Until recently, our understanding was that their natural history was not ideal. For example, two decades ago, we believed that the risk of aneurysmal rupture was 3% per year. This risk was an overestimation for most aneurysms. A number of large prospective studies not only provide a better risk assessment, but more importantly, they stratify the lesions according to

specific characteristics. We can now individually tailor the management of these lesions by providing a more accurate assessment of their natural history risk.

The other side of the equation is the risk of treatment. New microsurgical, endoscopic, endovascular, and radiosurgical approaches provide important options that allow us to tailor the therapy to both the specifics of the patient and the specifics of the target lesion. The University of Pittsburgh Department of Neurological Surgery has an internationally renowned faculty, including experts in the management of these complex lesions. We are proud to be a regional, national, and international referral and training center for the management of cerebrovascular disorders. As leaders in this field, we are intricately involved with developing and implementing constant change.

Robert M. Friedlander, MD, MA
Chairman and Walter E. Dandy Professor of Neurological Surgery
Co-Director, UPMC Neurological Institute

Faculty

Chairman

Robert M. Friedlander, MD, MA

Professors

C. Edward Dixon, PhD
 Peter C. Gerszten, MD, MPH
 L. Dade Lunsford, MD
 John J. Moossy, MD
 Ajay Niranjani, MD, MBA
 David O. Okonkwo, MD, PhD
 Ian F. Pollack, MD
 Mingui Sun, PhD

Associate Professors

Jeffrey Balzer, PhD
 Donald J. Crammond, PhD
 Johnathan Engh, MD
 Juan C. Fernandez-Miranda, MD
 Paul A. Gardner, MD
 D. Kojo Hamilton, MD
 Adam S. Kanter, MD, FAANS
 Raymond F. Sekula Jr., MD, MBA
 Parthasarathy D. Thirumala, MD
 Elizabeth C. Tyler-Kabara, MD, PhD

Assistant Professors

Sameer Agnihotri, PhD
 Nduka Amankulor, MD
 Diane L. Carlisle, PhD
 Pat Conway, PhD
 (Executive Administrator)
 Avniel Ghuman, PhD
 Paola Grandi, PhD
 Stephanie Greene, MD
 Bradley Gross, MD
 Luke Henry, PhD
 Brian Jankowitz, MD
 Edward A. Monaco III, MD, PhD
 Ava Puccio, PhD, RN
 R. Mark Richardson, MD, PhD
 Mandeep Tamber, MD, PhD
 Fang-Cheng (Frank) Yeh, MD, PhD

Clinical Professors

Adnan A. Abila, MD
 Matt El-Kadi, MD, PhD
 Joseph C. Maroon, MD
 Daniel A. Wecht, MD, MSc

Clinical Associate Professors

Michael J. Rutigliano, MD, MBA
 David S. Zorub, MD

Clinical Assistant Professors

J. Brad Bellotte, MD
 Daniel M. Bursick, MD
 David L. Kaufmann, MD
 Vincent J. Miele, MD
 Monte B. Weinberger, MD

Research Associate Professor

Hideyuki Kano, MD, PhD

Research Assistant Professors

Yue-Fang Chang, PhD
 Wendy Fellows-Mayle, PhD
 Esther Jane, PhD
 Wenyan Jia, PhD
 Daniel Premkumar, PhD
 Hong Qu Yan, MD, PhD

Clinical Instructors

Jeffrey W. Bost, PA-C
 Erin E. Paschel, PA-C

Chief Residents

Christopher Deibert, MD
 Zachary Tempel, MD
 Nathan Zwagerman, MD

Contact Us

Department of Neurological Surgery

UPMC Presbyterian
 Suite B-400
 200 Lothrop St.
 Pittsburgh, PA 15213
 412-647-3685

Editor: Peter C. Gerszten, MD, MPH

Website: neurosurgery.pitt.edu

Email: neuroinfo@upmc.edu

 Like us on Facebook @ [facebook.com/pitt.neurosurgery](https://www.facebook.com/pitt.neurosurgery)

 Visit us on youtube @ [youtube.com/neuroPitt](https://www.youtube.com/neuroPitt)

Dural Arteriovenous Fistulas: One of Neurosurgery's Great Masqueraders

by **Bradley Gross, MD**

Dural arteriovenous fistulas (DAVFs) are a subgroup of central nervous system vascular malformations composed of meningeal arteries that shunt within the dural leaflets into a venous sinus and/or leptomeningeal vein. While some may be asymptomatic and discovered incidentally, others may present in a variety of ways, including pulsatile tinnitus; ocular symptoms such as chemosis, proptosis, or cranial nerve palsies; intracranial venous hypertension; or even frank intracranial hemorrhage. Symptoms of venous hypertension may include seizures, dementia, Parkinsonism, or stroke-like symptoms, making DAVFs an intriguing central nervous system “masquerader.”

I have researched DAVFs since residency. At that time, we performed a systematic pooled analysis of several cohorts of patients with DAVFs. Across 395 fistulas, we elucidated novel demographic information and provided stratified, annualized hemorrhage rates for these lesions by subtype. Reinforcing prior studies, we found that cortical venous drainage was a significant risk factor for hemorrhage. In addition, we found that venous ectasia and symptomatic presentation were also independent risk factors for hemorrhage. In a separate study, we evaluated and demonstrated the safety and feasibility of surgical treatment of well-selected, high-risk fistulas. In another study, pooling results from the literature for 558 DAVFs treated with stereotactic radiosurgery, including a substantial cohort of patients who had been treated at UPMC, we found an overall obliteration rate of 71%. In particular, cavernous sinus DAVFs and those without cortical venous drainage had higher obliteration rates and lower complication rates.

Although stereotactic radiosurgery and surgery are potential treatment options for DAVFs, minimally invasive endovascular therapy is the mainstay, first-line approach for these lesions. The goal of any treatment approach is to close off the fistula point — either by surgical disconnection or endovascular occlusion with Onyx®, glue, or coils.

Onyx is a well-known endovascular embolisate for arteriovenous malformations; however its application to DAVFs has truly revolutionized their treatment. During my fellowship at the Barrow Neurological Institute, we evaluated a 20-year, single-institution endovascular treatment experience with 260 DAVFs. Through this analysis, we illustrated that the usage of Onyx significantly increased obliteration rates, widened the spectrum of fistulas that could be treated by endovascular means, and increased the ability to treat these fistulas through simple, single-pedicle transarterial approaches. We demonstrated a simple “80% rule” — approximately 80% of fistulas were obliterated endovascularly after the introduction of Onyx, and 80% of patients with either pulsatile tinnitus and/or ocular symptoms had significant improvement or resolution of their symptoms after endovascular treatment.

UPMC provides the full range of treatment approaches for DAVFs, with exceptional experience in endovascular treatment, surgical treatment, and of course radiosurgical options (see Figure 1). We are continuing research in the natural history and optimal treatment of these lesions, both at an institutional level and at a national level as part of a multicenter dural arteriovenous fistula consortium. Looking to the future, continued research into their natural history and optimal treatment, particularly in the setting of ongoing novel endovascular device development, makes this an exciting time to both study and treat these central nervous system “masqueraders.”

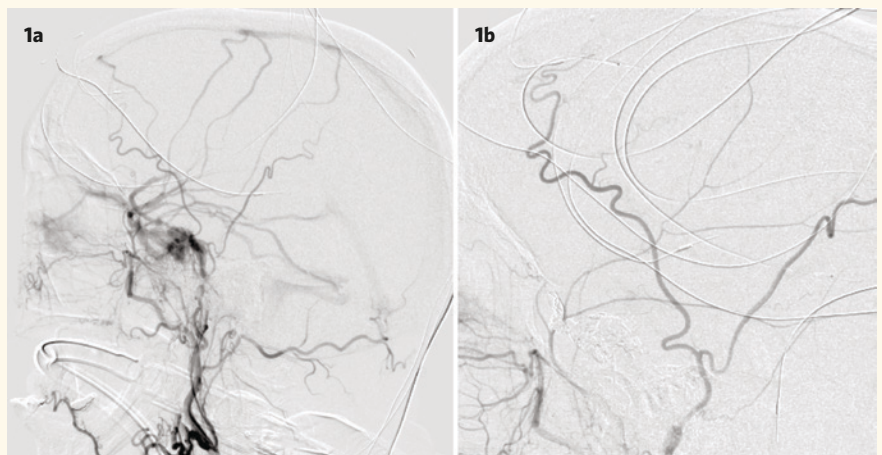


Figure 1. The angiogram on the left (1a) demonstrates a “high risk” dural arteriovenous fistula that was also causing significant visual symptoms. After transvenous endovascular treatment at UPMC with coils and Onyx, symptoms resolved and the follow-up angiogram on the right (1b) confirms complete closure of the fistula.

Extending the Role of the Neuroendovascular Surgeon in a Deployed Environment

by Phillip V. Parry, MD

(Editor's note: Dr. Parry is a 2015 graduate of the University of Pittsburgh's neurological surgery residency program.)

Throughout Operation Enduring Freedom (OEF) from October 2001 through December 2014 and the continued combat operations conducted under the name Operation Freedom's Sentinel (OFS) from January 2015 to present, the Craig Joint Theater Hospital (CJTH) at Bagram Airfield in Parwan Province, Afghanistan, has served as the only hospital for all deployed active duty members of the International Security Assistance Force (ISAF), the thousands of international contractors who live on base, and local non-combatant Afghan nationals to receive definitive surgical care. Under the current medical rules of engagement for the OFS mission, emergent care for the neurosurgical patient at this hospital focuses on preservation of life, limb, and eyesight irrespective of the patient's country of origin, military branch, or combatant or non-combatant status. Elective neurosurgery for local Afghan nationals is highly restricted at CJTH, requiring a stringent screening process.

In combination with these restrictions, the marked drawdown in combat operations, troop number, and the military footprint in Afghanistan, the volume of emergent and elective neurosurgical operations at CJTH has dramatically decreased. The overall decrease in surgical volume under OFS has limited the hospital's ability to provide specialty care in several surgical service lines. For example, there are no longer positions available for



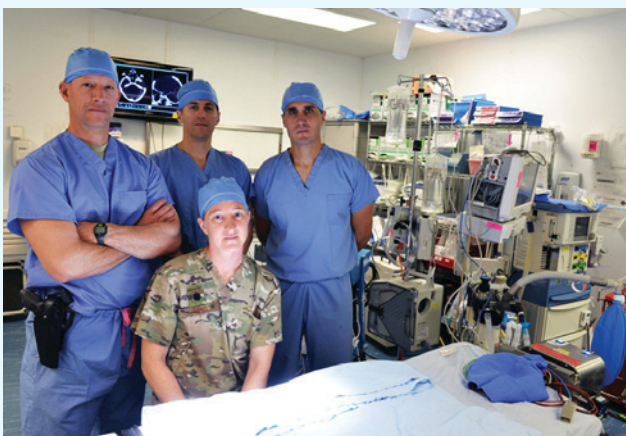Chad Garland, ©2016 Stars and Stripes, All Rights Reserved.

Surgeons of the U.S. Air Force's 455th Expeditionary Medical Group at Bagram Airfield stand in Warrior Way outside Craig Joint Theater Hospital on June 10, 2016. Pictured left to right: Lt. Col. Stephen Maturo, Maj. Phillip Parry, Lt. Col. Jamie Rand, and Lt. Col. Chance Henderson.

vascular surgery, OBGYN, cardiothoracic surgery, or oral maxillofacial surgery at CJTH, now that the mission focus of medical care under OFS has been restricted. Consequently, CJTH is no longer able to provide the full spectrum of open and peripheral neuroendovascular services previously available during OEF. While traditional neurosurgical case volumes have diminished considerably, there continue to be new and interesting challenges that require the neurosurgeon's skill set to fill the vacancies left behind from the eliminated surgical subspecialty positions. Since arriving in theater in April 2016 at CJTH — a challenging, resource poor, war-like environment — I have begun to amass a series of endovascular cases in which patient care was aided by my neuroendovascular surgery fellowship training.

One of my first patients in theater suffered a pulmonary embolus with concomitant deep venous thrombosis, necessitating an inferior vena cava (IVC) filter. Though we did not have an interventional radiologist or a vascular surgeon available to install the filter, we did have several of these devices in the storeroom from years prior. Using the principles and practices of my neuroendovascular surgery training, I was able to successfully deploy the filter and retrieve it three months later when the patient no longer required the device (see Figure 1 on Page 5).

(Continued on Page 5)



Chad Garland, ©2016 Stars and Stripes, All Rights Reserved.

Surgeons of the U.S. Air Force's 455th Expeditionary Medical Group at Bagram Airfield in the operating room at Craig Joint Theater Hospital on June 10, 2016. Pictured here, back row, (left to right): Lt. Col. Chance Henderson, Maj. Phillip Parry, and Lt. Col. Stephen Maturo. Front row: Lt. Col. Jamie Rand.

Equipped with two Philip's fluoroscopes and a host of leftover peripheral vascular catheters, wires, stents, and balloons, I was able to cobble together a bi-plane angiosuite (see Figure 2), which helped tremendously in the pre-operative planning for the resection of a ruptured occipital arteriovenous malformation (AVM). Furthermore, intraoperative angiography using the same bi-plane arrangement ensured a complete resection of the AVM, greatly facilitating management of the patient's post-operative course.

As one of the busiest primary stroke centers in the country, the high volume of interventional stroke care I performed as a fellow at University of Pittsburgh School of Medicine enabled me to apply similar principles of clot retrieval to patients with peripheral vascular thromboses. In a case involving a gunshot wound to the left femur with a mid-femur fracture, the patient had a tourniquet applied for 3.5 hours prior to arrival at our hospital. After the tourniquet was released during his orthopedic surgery, the patient lost pulses at his popliteal, dorsalis pedis, and tibialis anterior. An intraoperative angiogram of the left lower extremity showed a large thrombus at the distal popliteal artery. Using aspiration catheters typically reserved for intracranial clot retrieval, I was able to remove the thrombus (see Figure 3) and revascularized the patient's lower extremity, obviating the need for an open vascular thrombectomy.

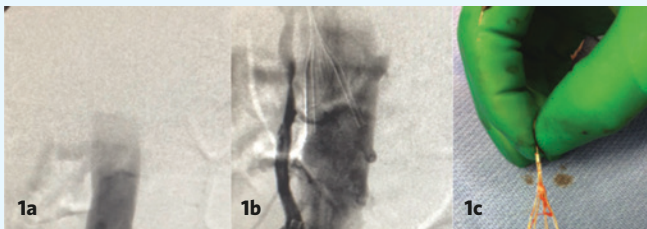

Figure 1. Intraoperative digital subtraction angiography (DSA) of distal abdominal aorta (1a) pre-IVC and post-IVC deployment (1b). Intraoperative photo of IVC retrieval three months after placement (1c).

Operating in austere environments requires creativity, performing outside of one's comfort zone, and making the most out of the resources available. Although the total number of surgical subspecialists in theater at CJTH has been reduced, there continues to be a need for the services they provide. Extending the role of the neuroendovascular surgeon in theater by applying neuroendovascular principles to a variety of peripheral and cerebrovascular cases helps to fill the subspecialty gap left behind by the absence of interventional radiologists and vascular surgeons. The success of these challenging cases is a testament to the excellent training afforded to the residents and fellows at the University of Pittsburgh.

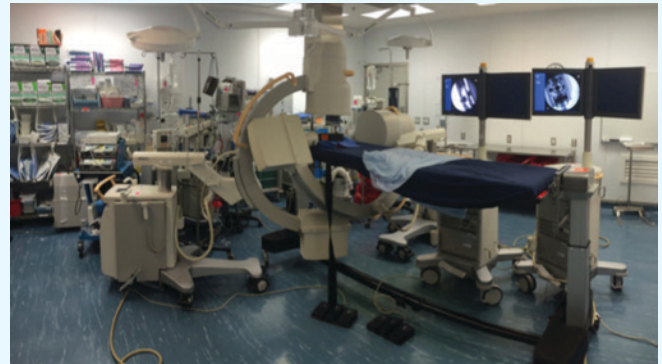

Figure 2. Two Philips C-arm fluoroscopes positioned perpendicularly to each other near a radiolucent Jackson table to simulate the workflow for interventional cases. Note the lateral fluoroscopic arm canted toward the foot of the bed in order to prevent the two machines from colliding. The displays show anteroposterior and lateral images taken simultaneously with overlapping regions of interest.

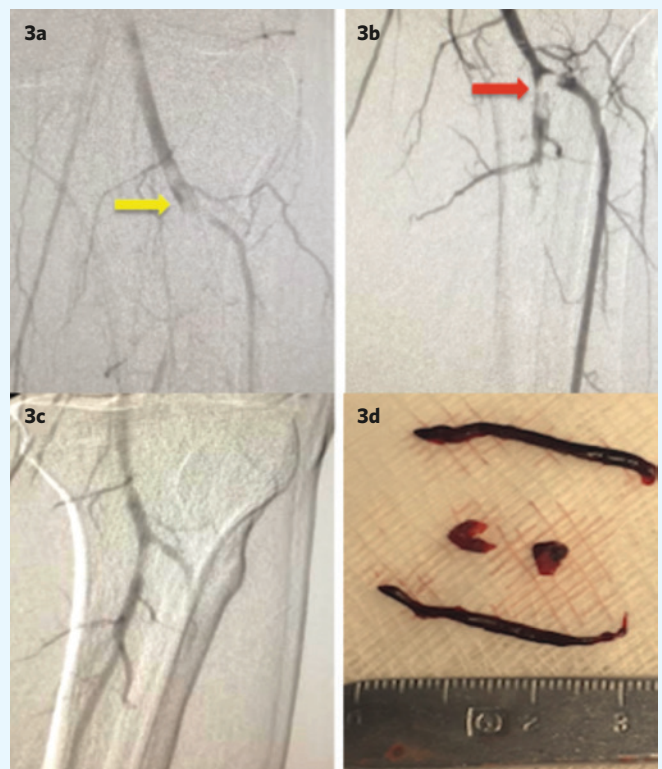


Figure 3. Intraoperative DSA of left popliteal artery showing occlusive thrombus at the bifurcation (yellow arrow) and no filling of the peroneal artery (3a). Left popliteal after one pass with an aspiration catheter (3b); subocclusive thrombus remains at the bifurcation (red arrow). Repeat DSA of left popliteal after second pass with no remaining thrombus at the bifurcation (3c). Thrombus removed (3d) during two passes with aspiration catheters.

Improving Outcomes in the Acute Stroke Population with Endovascular Therapy

by Ashutosh P. Jadhav, MD, PhD

Ischemic stroke continues to be a leading cause of mortality and permanent disability. In particular, decreased blood flow and resultant ischemia in the setting of acute intracranial large vessel occlusion is associated with the worst outcomes, requiring urgent clinical attention. Intravenous recombinant tissue plasminogen activator (IV t-PA) remains the only FDA-approved medication for patients presenting within three hours of the onset of symptoms; however, off-label use can be extended up to 4.5 hours in eligible patients. Unfortunately, the efficacy of IV t-PA is limited and does not always lead to fast or complete clot disruption. Furthermore, this therapy is only approved for select patients, who must present within early time windows. The need has arisen for faster and more effective modes of clot retrieval, in particular a percutaneous approach with intra-arterial thrombectomy.

Six recently published randomized clinical trials have unequivocally established the benefit of mechanical clot retrieval with stent retrievers for acute ischemic stroke. In particular, a pooled analysis of patients enrolled in five of these trials has shown that patients presenting with moderate to severe clinical deficits in the setting of large vessel occlusion who are treated with standard medical therapy (which, in the majority of cases, included IV t-PA) have superior outcomes when treated in conjunction with endovascular therapy as compared to patients who received standard medical therapy alone. For every 2.6 stroke patients who receive thrombectomy, one patient experiences a reduced degree of disability. A similar benefit was observed when medical therapy included IV t-PA (versus no IV t-PA). In contrast, 29 patients must be treated with percutaneous coronary interventions to prevent death, recurrence of myocardial infarction, and stroke in just one patient in the setting of an ST elevation acute myocardial infarction. Given these results, the American Heart Association/American Stroke Association recommends intra-arterial (IA) therapy for all eligible patients presenting within six hours (Class IA recommendation). In September 2016, the FDA recognized stent retrievers as devices with the potential to both retrieve clots and reduce the devastating disabilities associated with strokes.

These landmark developments have had a significant impact on current stroke care and have greatly expanded therapeutic options. The UPMC Center for Neuroendovascular Therapy, in partnership with the UPMC Stroke Institute, has played a leading role in these developments, having helped lead three of the six trials (REVASCAT trial, ESCAPE trial, and SWIFT PRIME trial) and acting as a major enrolling site in two of these trials (No. 2 enroller in the SWIFT PRIME trial and No. 1 U.S. enroller in the ESCAPE trial).

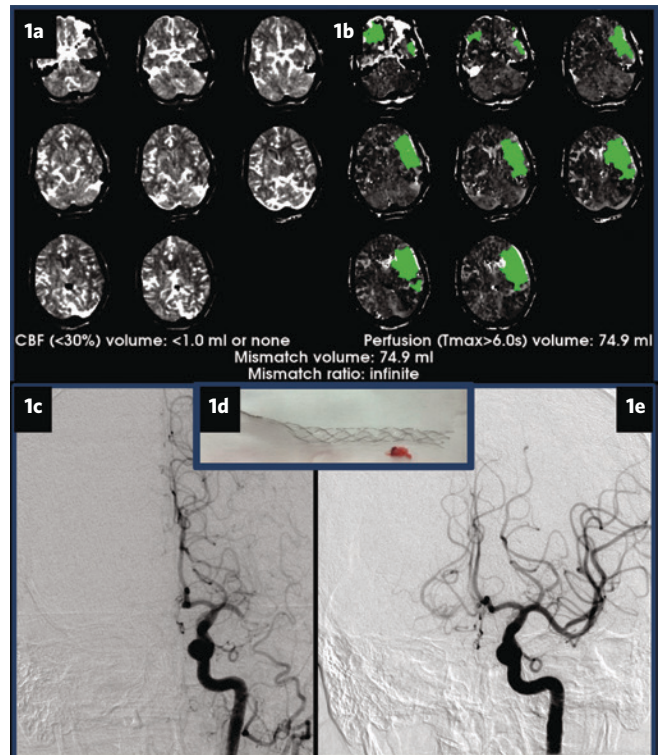


Figure 1. This figure demonstrates a blockage in the left middle cerebral artery (1c) in a 60-year-old woman presenting with “wake up” symptoms of right-sided weakness and language difficulty. Perfusion imaging demonstrates no core infarct (1a). However, there is a large territory at risk (penumbra, 1b). After IA clot therapy with a stent retriever device (1d), the middle cerebral artery is now patent with improved flow (1e). Following treatment, this patient had a normal clinical exam and was discharged home.

Key Takeaways

- Stroke therapy is most effective if delivered early.
- IV therapy may benefit a subset of patients, but is only applicable up to 4.5 hours from symptoms onset.
- IV therapy is the only therapy available in certain stroke subtypes (small vessel occlusions), but may be ineffective as monotherapy for large vessel occlusions.
- Combined IV/IA therapy is recommended for patients presenting within six hours of symptoms onset.
- New clinical trials are assessing the role of IA therapy in patients presenting within six to 24 hours of symptoms onset.

(Continued on Page 8)

News & Notes

FDA Approves ImPACT Test Devices

The U.S. Food and Drug Administration has permitted marketing of two new devices to assess a patient's cognitive function immediately after a suspected brain injury or concussion. The Immediate Post-Concussion Assessment and Cognitive Testing (ImPACT®) and ImPACT Pediatric® are intended to be part of the medical evaluation that doctors perform to assess signs and symptoms of a head injury.

ImPACT and ImPACT Pediatric are not intended to diagnose concussions or determine appropriate treatments. Instead, the devices are meant to test cognitive skills such as word memory, reaction time, and word recognition, all of which could be affected by a head injury. The results are compared to an age-matched control database or a patient's pre-injury baseline scores, if available.

"This is a very important step in our testing and treatment of concussions," said **Joseph C. Maroon, MD**, concussion expert, Pittsburgh Steelers neurosurgeon, and Heindl Scholar in Neuroscience at the University of Pittsburgh School of Medicine. "With ImPACT Pediatric, we now can test the millions of kids between five and 12 who heretofore had no test for baseline concussions."

Congratulations

Robert Friedlander, MD, was honored as a "Doctor of Distinction" by the Ladies Hospital Aid Society at the group's 118th Brain Gain Gala on September 8.

Ajay Niranjana, MD, MBA, received the Allen Humphrey Excellence in Mentoring Award from the University of Pittsburgh. The award is presented to a Dean's Summer Research Program (DSRP) mentor who demonstrated exemplary care and commitment in all aspects of DSRP student mentoring.

PGY-1 resident **Kamil W. Nowicki, MD**, was awarded two grant awards totaling \$35,000 from the Brain Aneurysm Foundation for his project, "Targeting Platelet Inflammatory Axis in Cerebral Aneurysm Progression and Healing." The awards are part of the foundation's Chairs of Research Program that funds basic scientific research directed at early detection, improved treatment modalities, and technological advances.

In a study recently published in *Neurosurgical Focus*, two articles authored by **Peter Gerszten, MD**, were ranked among the most cited journal articles, based on citations per year, on metastatic spine disease, dating back to 1940. His 2005 article on radiosurgery for spinal metastases was ranked second.

Joseph C. Maroon, MD, completed the Muncie 70.3 Ironman on July 9, taking first place in his division. He is currently ranked second nationally, and fourth globally, in his age division, M75-79.

PGY-6 resident **Georgios A. Zenonos, MD**, received the best presentation award at the twelfth annual University of Pittsburgh Department of Neurological Surgery Stuart Rowe Society Lectureship and Resident Research Day held on October 19. PGY-6 resident **Gregory Weiner, MD**, received the runner-up award. It was the second year in a row that Dr. Weiner was honored with the runner-up award.

Special Lectures and Appearances

D. Kojo Hamilton, MD, was a distinguished alumni lecturer at the University of Virginia School of Medicine on June 20.

Joseph C. Maroon, MD, was a special guest speaker at "Thriving Under Adversity," a sports performance workshop hosted by Red Bull, in Santa Monica, Calif. on September 13.

Paul Gardner, MD, was a special invited speaker at the European Association of Neurosurgical Societies 2016 Conference held in Athens, Greece; and at Skull Base Con 2016 — the annual conference of skull base society of India, both in September.

Juan C. Fernandez-Miranda, MD, was an honored guest at the Brazilian Congress of Neurosurgery from September 5-9, and at the Japanese Congress of Neurosurgery from September 29 - October 1. He was also a visiting professor at the Fukuoka University Department of Neurosurgery in Fukuoka City, Japan on October 2.

In the News

Robert Friedlander, MD, was featured in a KDKA-TV story on September 8 that showed how High Definition Fiber Tracking (HDFT) helped save the vision of a patient diagnosed with a glioblastoma.

L. Dade Lunsford, MD, was featured in a WPXI-TV "Proud to be from Pittsburgh" segment on August 5 that discussed how a former patient's experience with the Gamma Knife expert inspired a career in medicine.

David Okonkwo, MD, PhD, was featured in a *Pittsburgh Post-Gazette* concussion article, October 30, that reported on a *Journal of Neurosurgery* paper that stated concussions are treatable, a major first step in medical literature.

Improving Outcomes with Endovascular Therapy *(Continued from Page 6)*

While the evidence supports the use of mechanical embolectomy for patients presenting within six hours of the onset of symptoms in the anterior circulation, the benefit of IA therapy in patients presenting beyond this time frame remains unproven. However, preliminary data indicate that in a subset of patients consisting of those with favorable collateral flow and only a small established infarct, this approach is safe and may offer clinical benefit.

To address this area of uncertainty, three clinical trials are now focusing on the benefit of standard medical therapy alone versus adjunctive IA therapy in patients presenting with “wake up” strokes or with stroke symptoms beyond six hours of initial presentation. In particular, the DAWN trial is a global study designed and co-led by Tudor Jovin, MD, director of the UPMC Stroke Institute and co-director of the UPMC Center for Neuroendovascular Therapy, and Raul Nogueira, MD, director

of neuroendovascular service at Grady Memorial Hospital/Emory University, in Atlanta, Ga. The trial aims to enroll a maximum of 500 patients presenting between six and 24 hours from symptoms onset, selected based on proof of large vessel occlusion in the anterior circulation, moderate to severe clinical deficit, and evidence of a small infarct on advanced neuroimaging studies (CT perfusion or MRI) measured via automated software (RAPID). The patients will be randomized to standard medical therapy alone versus standard medical therapy in conjunction with mechanical embolectomy performed with the Trevo® retriever device. UPMC is currently the lead enrolling site. Proving the benefit of IA therapy in this population would lead to a paradigm shift in patient selection for IA therapy from time-based to physiology-based, in which time windows would be of secondary importance.

Free Online CME

To take the CME evaluation for this issue, visit our education website: UPMCPhysicianResources.com/Neurosurgery.

A world-renowned health care provider and insurer, Pittsburgh-based UPMC is inventing new models of patient-centered, cost-effective, accountable care. It provides nearly \$900 million a year in benefits to its communities, including more care to the region's most vulnerable citizens than any other health care institution. The largest nongovernmental employer in Pennsylvania, UPMC integrates 60,000 employees, more than 20 hospitals, more than 500 doctors' offices and outpatient sites, and a more than 3 million-member Insurance Services Division, the largest medical and behavioral health services insurer in western Pennsylvania. Affiliated with the University of Pittsburgh Schools of the Health Sciences, UPMC ranks No. 12 in the prestigious *U.S. News & World Report* annual Honor Roll of America's Best Hospitals. UPMC Enterprises functions as the innovation and commercialization arm of UPMC, while UPMC International provides hands-on health care and management services with partners in 12 countries on four continents. For more information, go to UPMC.com.

USNW502762 CG/QDD 11/16 © 2016 UPMC

UPMC is proud to be the only hospital in western Pennsylvania to be named to *U.S. News & World Report's* prestigious national Honor Roll for excellence in 15 specialty areas, including neurology and neurosurgery. For more information about our programs, continuing medical education, Video Rounds, news, and events, please visit UPMCPhysicianResources.com/Neurosurgery.

